

Available online at www.sciencedirect.com

ScienceDirect

journal homepage: www.elsevier.com/locate/ajur

Original Article

Transperineal laser ablation of the prostate as a treatment for benign prostatic hyperplasia and prostate cancer: The results of a Delphi consensus project

Andrea Cocci ^a, Marta Pezzoli ^{b,*}, Fernando Bianco ^c,
 Franco Blefari ^d, Pierluigi Bove ^{e,f}, Francois Cornud ^g,
 Gaetano De Rienzo ^h, Paolo Destefanis ⁱ, Danilo Di Trapani ^j,
 Alessandro Giacobbe ^k, Luca Giovanessi ^l, Antonino Laganà ^m,
 Giovanni Lughezzani ^{n,o}, Guglielmo Manenti ^{p,q},
 Gianluca Muto ^a, Gianluigi Patelli ^r, Novello Pinzi ^s,
 Stefano Regusci ^{t,u}, Giorgio I. Russo ^v, Juan I.M. Salamanca ^{w,x},
 Matteo Salvi ^a, Luigi Silvestri ^y, Fabrizio Verweij ^z,
 Eric Walser ^{aa}, Riccardo G. Bertolo ^{f,ab}, Valerio Iacovelli ^f,
 Alessandro Bertaccini ^{ac}, Debora Marchiori ^{ac}, Hugo Davila ^{ad,ae},
 Pasquale Ditunno ^h, Paolo Gontero ^{af}, Gennaro Iapicca ^{ag},
 Theo M De Reijke ^{ah}, Vito Ricapito ^{ai}, Pierluca Pellegrini ^y,
 Andrea Minervini ^a, Sergio Serni ^a, Francesco Sessa ^a

^a Department of Urology, Careggi Hospital, University of Florence, Florence, Italy

^b Urology Section, University of Florence, Florence, Italy

^c Urological Research Network, Miami, FL, USA

^d Urology Section, Prato Hospital, Prato, Italy

^e Torvergata Oncoscience Research Centre of Excellence, TOR, Department of Experimental Medicine, University of Rome Tor Vergata, Rome, Italy

^f Department of Urology, San Carlo di Nancy Hospital, Rome, Italy

^g Department of Radiology, Hôpital Cochin, Paris Descartes University, Paris, France

^h Urology and Andrology Unit II, Department of Emergency and Organ Transplantation, University of Bari, Bari, Italy

ⁱ Unit of Urology, Città della Salute e della Scienza Hospital, University of Turin, Turin, Italy

^j Urology Unit, Buccheri La Ferla Fatebenefratelli Hospital, Palermo, Italy

^k Department of Urology, Humanitas Gradenigo Hospital, Turin, Italy

* Corresponding author.

E-mail address: marta.pezzoli@unifi.it (M. Pezzoli).

Peer review under responsibility of Tongji University.

<https://doi.org/10.1016/j.ajur.2023.07.001>

2214-3882/© 2024 Editorial Office of Asian Journal of Urology. Production and hosting by Elsevier B.V. This is an open access article under the CC BY-NC-ND license (<http://creativecommons.org/licenses/by-nc-nd/4.0/>).

Please cite this article as: A. Cocci, M. Pezzoli, F. Bianco et al., Transperineal laser ablation of the prostate as a treatment for benign prostatic hyperplasia and prostate cancer: The results of a Delphi consensus project, Asian Journal of Urology, <https://doi.org/10.1016/j.ajur.2023.07.001>

- ^l Urology Unit, Surgical Department, Fondazione Poliambulanza Istituto Ospedaliero, Brescia, Italy
- ^m Department of Urology, "S. Giovanni Evangelista" Hospital, Tivoli, Italy
- ⁿ Humanitas Clinical and Research Center—IRCCS, Department of Urology, Rozzano, Italy
- ^o Department of Biomedical Sciences, Humanitas University, Pieve Emanuele, Italy
- ^p Department of Biomedicine and Prevention, University of Rome "Tor Vergata", Rome, Italy
- ^q Department of Diagnostic Imaging and Interventional Radiology, University of Rome "Tor Vergata", Rome, Italy
- ^r Department of Interventional Radiology, Pesenti-Fenaroli Hospital-ASST Bergamo Est, Alzano Lombardo, Italy
- ^s Department of Urology, University of Siena, Siena, Italy
- ^t Swiss International Prostate Center, Geneva, Switzerland
- ^u Clinique Générale Beaulieu, Geneva, Switzerland
- ^v Department of Urology, University of Catania, Italy
- ^w Department of Urology, Puerta de Hierro-Majadahonda University Hospital, Madrid, Spain
- ^x Lyx Institute of Urology, Universidad Francisco de Vitoria, Madrid, Spain
- ^y Department of Medico-Surgical Sciences and Biotechnologies, Sapienza University of Rome, Faculty of Pharmacy and Medicine, Urology Unit ICOT, Latina, Italy
- ^z Department of Urology, European Institute of Oncology (IEO) IRCCS, Milan, Italy
- ^{aa} Department of Radiology, Department of Surgery, University of Texas Medical Branch, Galveston, TX, USA
- ^{ab} Department of Urology, University of Verona, Azienda Ospedaliera Universitaria Integrata, Verona, Italy
- ^{ac} Department of Urology, IRCCS Azienda Ospedaliero-Universitaria di Bologna, Bologna, Italy
- ^{ad} Florida Healthcare Specialist, Urology and Minimally Invasive Surgery, Florida Cancer Specialist and Research Institute, Vero Beach, FL, USA
- ^{ae} Department of Surgery, Division of Urology and Gynecology, Sebastian River Medical Center, Sebastian, FL, USA
- ^{af} Department of Urology, Molinette Hospital, University of Torino School of Medicine, Turin, Italy
- ^{ag} Urology Unit, Santa Rita Clinic, Avellino, Italy
- ^{ah} Department of Urology, Amsterdam University Medical Centers, University of Amsterdam, the Netherlands
- ^{ai} Department of Urology, Policlinico di Bari, Bari, Italy

Received 23 January 2023; received in revised form 7 March 2023; accepted 6 April 2023

KEYWORDS

Transperineal laser ablation;
Prostate cancer;
Benign prostatic hyperplasia;
Delphi consensus

Abstract Objective: To evaluate transperineal laser ablation (TPLA) with Ecolaser® (Ecolaser® TPLA, Elesta S. p.a, Calenzano, Italy) as a treatment for benign prostatic hyperplasia (BPH) and prostate cancer (PCa) using the Delphi consensus method.

Methods: Italian and international experts on BPH and PCa participated in a collaborative consensus project. During two rounds, they expressed their opinions on Ecolaser® TPLA for the treatment of BPH and PCa answering online questionnaires on indications, methodology, and potential complications of this technology. Level of agreement or disagreement to reach consensus was set at 75%. If the consensus was not achieved, questions were modified after each round. A final round was performed during an online meeting, in which results were discussed and finalized.

Results: Thirty-two out of forty invited experts participated and consensus was reached on all topics. Agreement was achieved on recommending Ecolaser® TPLA as a treatment of BPH in patients with ample range of prostate volume, from <40 mL (80%) to >80 mL (80%), comorbidities (100%), antiplatelet or anticoagulant treatment (96%), indwelling catheter (77%), and strong will of preserving ejaculatory function (100%). Majority of respondents agreed that Ecolaser® TPLA is a potential option for the treatment of localized PCa (78%) and recommended it for low-risk PCa (90%). During the final round, experts concluded that it can be used for intermediate-risk PCa and it should be proposed as an effective alternative to radical prostatectomy for patients with strong will of avoiding urinary incontinence and sexual dysfunction. Almost all participants agreed that the transperineal approach of this organ-sparing technique is safer than transrectal and transurethral approaches typical of other techniques

(97% of agreement among experts). Pre-procedural assessment, technical aspects, post-procedural catheterization, pharmacological therapy, and expected outcomes were discussed, leading to statements and recommendations.

Conclusion: Ecolaser® TPLA is a safe and effective procedure that treats BPH and localized PCa with satisfactory functional and sexual outcomes.

© 2024 Editorial Office of Asian Journal of Urology. Production and hosting by Elsevier B.V. This is an open access article under the CC BY-NC-ND license (<http://creativecommons.org/licenses/by-nc-nd/4.0/>).

1. Introduction

Transperineal laser ablation (TPLA) of the prostate using the Ecolaser® system (Ecolaser® TPLA, Elesta S. p.a, Calenzano, Italy) is a novel minimally invasive technique which provides a thermal ablation of the prostatic tissue thanks to laser–tissue interaction that induces cell death. The resulting coagulative necrosis leads to a post-necrotic reabsorption of the treated area [1–4].

Assuming that the mechanism of action of Ecolaser® TPLA could potentially reduce the volume of the transitional zone of the prostate, the clinical study by Patelli et al. [7] and following ones have evaluated TPLA for the treatment of symptomatic lower urinary tract symptoms (LUTS) secondary to benign prostatic obstruction (BPO), establishing that it is a safe and effective procedure including no significant impacting on sexual function [1,5–9].

Moreover, Ecolaser® focal laser ablation (FLA) system has been proposed as a promising procedure for the treatment of localized prostate cancer (PCa), with some advantages in comparison to other FLA techniques, such as multifiber treatment and local anesthesia [2].

Nevertheless, indications for the use of the Ecolaser® TPLA as a treatment for benign prostatic hyperplasia (BPH) and PCa are not yet defined as well as procedural protocols. For these reasons, experts in the field have been invited in an international collaborative project with the aim of using the Delphi consensus method to get to a consensus on these topics [10].

The Delphi consensus method is a process used to arrive at a group opinion or decision on a specific issue by surveying a panel of experts which responds to several rounds of questions. The responses are aggregated and shared with the group after each round, so that the experts can adjust their answers based on how they interpret the provided “group response”. The ultimate result is meant to be a true consensus of what the group thinks [10]. Delphi method in medical field has become a widely used process, especially when a new procedure appears in the panorama of treatments for a specific pathology.

Using the Delphi method, from March 1, 2022 to September 26, 2022, Italian and international experts have expressed their opinions on Ecolaser® TPLA as a treatment for BPH and PCa in terms of indications of use, pre-procedural assessment and prophylaxis, procedural aspects including anesthesiologic ones, post-procedural

catheterization and pharmacologic treatment, follow-up, and outcomes. The resulting group opinions are presented in this paper.

2. Materials and methods

The Delphi method was used to achieve consensus among a panel of experts.

A literature search on PubMed using (“TPLA” OR “transperineal laser ablation of the prostate”) AND (“BPH” OR “benign prostatic hyperplasia” OR “BPO” OR “benign prostatic obstruction”) led to 14 articles, of which six were eligible after full-text screening; all studies were focused on Ecolaser® TPLA. A different search on PubMed using (“TPLA” OR “transperineal focal laser ablation”) AND (“PCa” OR “prostate cancer”) led to 24 results, of which five were eligible after full-text screening; one study was on Ecolaser® TPLA, four on other transperineal FLA techniques. Fig. 1 illustrates flow-chart for study selection. Panelists were selected based on their proven experience in clinical practice and research on the topic.

Online questionnaires were presented to participants in two subsequent rounds between March 01, 2022 and July 31, 2022 using an online survey platform (www.welphi.com, Lisbon, Portugal). Selected topics were indications for the use of Ecolaser® TPLA in the treatment of BPH and PCa, pre-procedural assessment and prophylaxis, technical aspects of the procedure, post-procedural catheterization and pharmacologic treatment, follow-up, outcomes, and general considerations about Ecolaser® TPLA (list of questions is shown in [Supplementary file](#)). Participants were administered Likert scale questions and open questions. For open questions, responses were analyzed to select prevailing experts’ opinions. For Likert scale questions, in the first round, possible responses were indicated as “strongly agree”, “agree”, “neither agree nor disagree”, “disagree”, and “strongly disagree”; in the second round, these were “strongly agree”, “mostly agree”, “mostly disagree”, and “strongly disagree”. For some questions, participants have been asked to comment on their responses; these comments were analysed to highlight prevailing experts’ opinions. To achieve consensus, over 75% of respondents needed to converge on a category of agreement or disagreement; descriptive statistics were used to determine the response rate of each topic.

Final round was performed via an online meeting held by the platform Zoom® (Zoom Video Communications, San

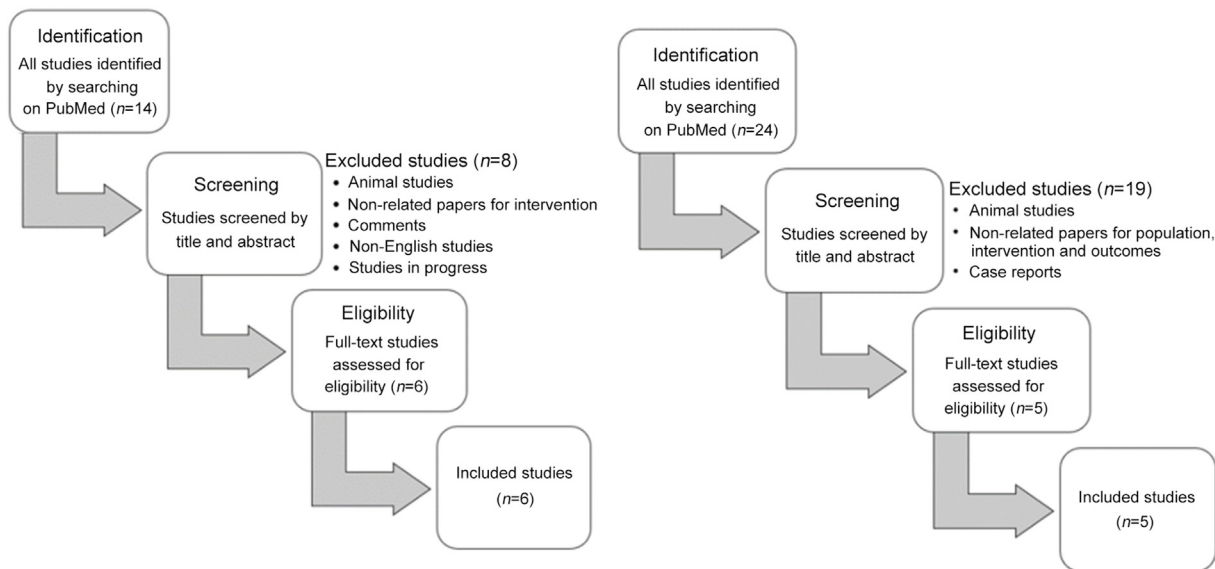


Figure 1 Flow-chart selection for studies on TPLA for the treatment of benign prostatic hyperplasia or benign prostatic obstruction (on the left) and prostate cancer (on the right). TPLA, transperineal laser ablation.

Jose, CA, USA) on September 26, 2022, when the results of previous rounds were presented and questions that had not yet achieved consensus were discussed, leading to the final result.

3. Results

3.1. Demographics of consensus participants

Forty Italian and international experts were invited and agreed to participate. Response rate was 80% (32/40) in the first round and 77.5% (31/40) in the second round. Twenty-eight out of 32 (87.5%) participants were urologists and 4/32 (12.5%) interventional radiologists. Eighteen out of 32 (56.2%) worked in hospital, 11/32 (34.4%) in private practice, and 3/32 (9.4%) in both hospital and private practice. Twelve out of 32 (37.5%) treated more than 150 LUTS and/or BPO patients per year; 19/32 (59.4%) reported to use TURP for the treatment of BPO frequently; 31/32 (96.9%) reported to use in their practice at least one laser treatment for BPO among Echolaser® TPLA, photo-vaporization of the prostate, holmium laser enucleation prostate, or thulium laser enucleation of the prostate. Six out of 32 (18.8%) treated more than 50 PCa patients per year with focal therapy and 17/32 (53.1%) reported to use Echolaser® TPLA as focal therapy for PCa.

3.2. TPLA for BPO

3.2.1. Pre-operative indications

The majority of the respondents (80%) recommended Echolaser® TPLA for the treatment of BPO in case of prostate volume of <40 mL in patients who do not want to

undergo medical therapy or do not fully respond to it, if there are urodynamic signs suggestive of obstruction.

The consensus agreed that the procedure can be used for a prostate volume between 40 mL and 80 mL (90%), which is considered the ideal volume for the treatment, and for prostate volume of >80 mL (80%), providing a more extensive treatment. Further, Echolaser® TPLA can be carried out for the treatment of BPO in presence of a hyperplastic median lobe (>75%).

All experts considered Echolaser® TPLA favorable in both young patients who have a strong will of preserving the ejaculatory function (100%) and high-risk patients with comorbidities (100%) due to local anesthesia, short operation time, low rate of treatment-related complications, and short hospitalization. The procedure is considered safe and feasible in patients taking anticoagulant or antiplatelet drugs (96%); before the treatment, their suspension is recommended according to the patients' hemorrhagic and thrombotic risk (77%).

A pre-operative post-void residual (PVR) of >300 mL can be reduced using Echolaser® TPLA (>75%). The procedure is helpful in both patients with voiding and storage urinary symptoms (80%) and patients with chronic urinary infections that complicate BPO (>75%). Instead, it is not recommended in case of patient history of chronic prostatitis or ultrasound evidence of multiple prostatic calcifications (>75%).

Echolaser® TPLA can lead to the chance of removing the catheter in patients with indwelling bladder catheter (77%), usually from 7 days to 1 month after the treatment. Performing Echolaser® TPLA in patients who have persistent LUTS after undergoing other minimally invasive procedures is not recommended (>75%). Patients with PCa treated with hormonal therapy (androgen deprivation therapy) can

benefit from Ecolaser® TPLA for the managing of LUTS (77%); on the contrary, this is not suggested in association with radiation therapy (>75%).

Finally, Ecolaser® TPLA is a minimally invasive procedure that represents an alternative to medical therapy in patients who are not tolerant or not willing to adhere to it (100%).

3.2.2. Pre-procedural assessment and prophylaxis

Before the treatment, a urine culture was recommended in all patients (84%). Performing a urodynamic examination was suggested only in patients with indwelling catheter (>75%), while in elderly and comorbid patients, it was not considered necessary (>75%). Also, a pre-procedural urethroscopy was not advised (>75%). Experts believed that an antibiotic prophylaxis must be administered (80%).

3.2.3. Procedural aspects

Experts would rather visit a center with good experience on Ecolaser® TPLA before doing it at their institution (83%). Moreover, they preferred that a company application specialist (84%) and/or an expert physician (87%) would support them during the early learning curve (usually 5–10 treatments, 75%).

To avoid urethral injuries, the use of a cooling catheter (3-way Foley) was recommended during the procedure (87%). For the same purpose, it was considered important to respect the safety distances, positioning the optic fiber far away from the urethra (>75%).

The planned dose can be delivered at the power of 3 Watt (W) (83%) to achieve an evident ultrasound effect on the prostatic tissue, but it can be increased up to 5 W to get a faster treatment (>75%).

The pull-back technique was suggested depending on the prostate size (90%), considering both axial and transversal dimensions; the number of pullbacks also depends on prostate size and shape (>75%). When performed properly, this technique can improve the outcome of the procedure (84%).

The software to plan and simulate the treatment was considered useful (77%) and allowed to shorten the learning curve, especially in placing the needles correctly (84%). When the software (Ecolaser Smart Interface-ESI, Elesta S. p.a., Calenzano, Italy) gave the indication to insert more needles, it was advised to follow the recommendation rather than use only one needle and perform multiple reinsertions (>75%). Furthermore, applying a fiber positioning aid such as a template or a grid can be helpful (>75%).

Anesthesia must be performed (77%). Lidocaine should be administered locally to skin and periprostatic tissue (>75%). The standard use of sedatives during the procedure is still controversial.

3.2.4. Post-procedural catheterization and pharmacologic treatment

Ecolaser® TPLA is an outpatient treatment (84%). Patients can be discharged on the same day of the procedure after 2–4 h on average (77%). It is recommended to maintain the catheter after the treatment in patients with indwelling catheter for 7–15 days (94%) and to place a catheter in

other patients for 7–10 days (93%), and to antagonize prostate inflammation and reduce the risk of acute urinary retention (AUR).

Regarding pharmacological treatment following the procedure, antibiotics are recommended for the first 5–7 days, corticosteroids and non-steroid anti-inflammatory drugs for a period that depends on how long the patient maintains the catheter (usually 7–15 days) (>75%). Moreover, experts suggested the use of alpha-blockers in the first weeks after the treatment, until symptoms relief generated by Ecolaser® TPLA starts manifesting (>75%).

3.2.5. Outcomes

The more common treatment-related complications observed are irritative and obstructive urinary symptoms, dysuria, AUR, infections, hematuria, and qualitative variation in seminal fluid. The less common ones are prostatic abscesses, necrosis, and bleeding; one expert reported a hypotensive shock occurred during the treatment.

The best parameters to assess the efficacy of Ecolaser® TPLA are International Prostatic Symptoms Score (IPSS), uroflowmetry parameters, and PVR (>75%). These elements should be evaluated during first follow-up, recommended 1–3 months after the procedure (>75%), and subsequent ones (>75%).

A consistent symptoms relief is expected 1–3 months after the treatment (>75%) with the maximum effect after 3–6 months (>75%).

According to their experience, experts confirmed that Ecolaser® TPLA preserves antegrade ejaculation (94%) and reduces or zeroes incontinence risk when compared to other treatments (87%).

3.2.6. General considerations

Based on the low complication rate, transperineal approach of Ecolaser® TPLA is considered safer than transurethral approaches of other techniques (81%). Furthermore, for the treatment of BPH, experts prefer an organ sparing technique like Ecolaser® TPLA, whose therapeutic intent is to eliminate symptoms while preserving tissue, rather than more aggressive approaches (>75%). Ecolaser® product manual is considered well-written and complete (93%).

3.3. TPLA for PCa

3.3.1. Pre-operative indications

Ecolaser® TPLA is recommended in specific cases of localized PCa (78%); its ideal use is for unilateral, monofocal, and small (<15 mm) PCa. It is highly recommended for low-risk PCa (Gleason score [GS] <7) (90%), but it can also be used for intermediate-risk PCa (GS 3+4) (>75%), extending the treatment area. On the contrary, it is not recommended for high-risk PCa (GS 4+3 and ≥8) (>75%).

In selected patients who have strong will of avoiding urinary incontinence and sexual dysfunction, it should be proposed as an effective alternative to radical prostatectomy (>75%). It can be performed for PCa with basal, apical, and anterior localization (80%, 76%, and 77%,

respectively). The procedure can treat simultaneously PCa and BPH in patients who also have concomitant LUTS (76%).

Echolaser® TPLA is recommended in patients previously treated with transurethral procedures (>75%), while its use is not supported in case of recurrent PCa after radical prostatectomy (>75%). Considering FLA in general, experts believed that it is an optimal approach to target a specific lesion only (77%), while it cannot target properly quadrant, hemi-gland, or subtotal ablations of the prostate (>75%, 81%, and 87%, respectively). FLA is recommended for patients whose life expectancy is less than 10 years and the treatment can delay local progression (84%).

3.3.2. Pre-procedural assessment and prophylaxis

As for the treatment of BPH, a urine culture (84%) and an antibiotic prophylaxis (80%) before the treatment are recommended.

Echolaser® TPLA treatment should be delivered only after a multiparametric MRI (mpMRI) staging (80%). In presence of a suspicious lesion on mpMRI, a histological confirmation is recommended before the procedure (100%). In this case, MRI/transrectal ultrasound fusion guided biopsy is considered the standard tool (91%). Even if an mpMRI suspicious lesion has already been sampled adequately by targeted biopsy, systematic biopsies remain necessary (83%).

3.3.3. Procedural aspects

Everything that has been described for BPH is valid for the treatment of PCa as well. In addition, experts believed that a radiologist supporting the operator during the procedure is not needed (>75%). Furthermore, using a fusion system during the treatment is mandatory (80%) and for FLA, it is important to respect an ablation margin (77%), which should be 5 mm.

3.3.4. Post-procedural catheterization and pharmacological treatment

Recommendations on catheterization and pharmacological treatment are the same as described above for the treatment of BPH, with the exception on what is said about alpha-blockers. Placing a catheter after the procedure is also recommended in the treatment of PCa (87%).

3.3.5. Outcomes

Main treatment-related complications are described in the "Outcomes" of Echolaser® TPLA for the treatment of BPH. mpMRI is the standard restaging technique after Echolaser® TPLA (84%) and it should be performed 3 months post-operatively (>75%). To establish a treatment success (defined by a residual GS 3+3), both negative mpMRI and random biopsy of the treatment area are required (80%). In case of recurrence, experts preferred to propose another treatment with Echolaser® TPLA rather than suggest other procedures (>75%).

3.3.6. General considerations

Transperineal approach of Echolaser® FLA is considered safer than transrectal or transurethral approaches of other

techniques (97%). Preserving both ejaculatory function (>75%) and external urethral sphincter function (>75%) are relevant reasons to choose Echolaser® FLA over radical treatments.

4. Discussion

Surgical treatment for BPH and localised PCa are evolving from open techniques to minimally invasive techniques, whose aim is to effectively treat the pathology while having as few side effects as possible, and a rapid recovery. Especially for BPH, a wide range of ultra-minimally invasive surgical techniques are now available including Urolift, Rezūm, and prostatic artery embolization. For localized PCa, some focal therapies have become part of urologists practice, such as high intensity focused ultrasound and cryoablation. In this scenario, Echolaser® TPLA has been proposed as an alternative ejaculation-sparing management for patients with BPH and a possible treatment for localised PCa.

Experts' consensus was achieved for using Echolaser® TPLA for the treatment of BPH in prostate volumes ranging from 40 mL to 80 mL (the volume range included in the studies published about the topic up to now) [1,5–9]. Less and higher prostate volumes were also considered suitable for the procedure, due to remarkable outcomes achieved in studies which included all volumes of ≥ 30 mL [1,5,7,8] and all volumes of ≤ 100 mL [6]. While Manenti et al. [1] excluded prostates with a median lobe, trials conducted by other authors suggested the feasibility and the efficacy of the treatment of such cases [5–7,9].

Lack of significant changes in the 5-item version of the International Index of Erectile Function score and improvements in Men's Sexual Health Questionnaire-Ejaculatory Dysfunction makes Echolaser® TPLA a good option for patients who have strong will of preserving the sexual function [1,6,9]. Local anesthesia, short operation time, low rate of treatment-related complications, and short hospitalization led to a wide consensus on its use in high-risk comorbid patients. In fact, the only pathologies considered as criteria of exclusion in most studies are neurological disorders that can impact on bladder function (e.g., Parkinson's disease, multiple sclerosis, and spinal cord injury), urethral strictures, and history of prostate and bladder cancer [1,6–9].

Strong consensus was reached on considering Echolaser® TPLA as an antiplatelet and anticoagulant-friendly treatment, due to its low invasiveness. Experts agreed on the suspension of these drugs before the procedure, always considering the balance between haemorrhagic and thrombotic risk in the individual patient. According to the literature, suspension is recommended in patients with high hemorrhagic risk, while in standard cases there is no need [1,6]. Moreover, literature indicates that high PVR (300–400 mL) is not an exclusion criterion for the procedure and can be remarkably reduced by the treatment [5,8].

Consensus was achieved on the possibility of using Echolaser® TPLA in patients with an indwelling catheter. Although these patients were excluded from some studies [1,6], two trials demonstrated the possibility of successfully removing the catheter after the procedure [5,9]. Pacella

et al. [5] reported only three cases needing a longer placement of the catheter due to AUR in 160 patients treated, of which 36 with indwelling catheter.

An argument of discussion during the final round was how to treat LUTS in patients with PCa. If the Echolaser® TPLA is a valuable tool in patients treated with androgen deprivation therapy, its association with radiotherapy is not recommended; despite one of the involved experts reported good outcomes by its use, the lack of experience in this field prevented its recommendation.

Furthermore, total agreement was achieved for suggesting Echolaser® TPLA for patients who do not fully respond to pharmacological treatment or are bothered by its side effects, thanks to the improvement in both IPSS and quality of life as well as low rate of complications and lack of negative impact in sexual function [1,5–9].

Experts agreed on performing a urine culture in all patients and executing an antibiotic prophylaxis to reduce treatment-related infectious complications. However, there was discussion on the need for urodynamic assessment before the procedure. Although in studies on the topic it was carried out for all patients [1,5–8], experts concluded that only patients with indwelling catheter would require it to exclude underactive bladder function. According to one of the experts, elderly and comorbid patients can benefit from urodynamic examination in terms of reduction of failure rate, because these conditions may be associated with a higher PVR that could reveal urodynamics signs of underactive bladder; this suggestion opens the door to further studies about the topic. Moreover, consensus was reached for lack of need for urethroscopy before the procedure, in accordance with literature [1,5–9].

Experts agreed on the help of an application specialist and/or an expert physician who supports the operator during the first procedures; moreover, they agreed that the learning curve is short for urologists and radiologists with experience in minimally invasive procedures for BPH. Consequentially, they quickly become fully autonomous with no need for further mentoring after the first procedures.

Based on literature, strong agreement was achieved on irrigating bladder and urethra using a three-way catheter to avoid thermal damages and on respecting a safety distance from the urethral wall. Studies reported an 8–10 mm fiber–urethral wall distance to protect it [1,5–9]. The pull-back technique, which consists in retracting fibers 10 mm along their trajectory to deliver additional energy, is considered useful for some prostate volumes and shapes. Nevertheless, its exact indications are not yet defined, preferring to leave the decision to perform it or not to the operator. About this topic, literature reports different operators' choices: according to Frego et al. [9], pull-back should be performed for prostate volume of >80 mL. Sessa et al. [3,4] also used it for large prostates, while de Rienzo et al. [6] considered it useful for prostates mainly developed in the longitudinal direction and Manenti et al. [1] performed it in all patients to widen the ablative area.

Some procedural aspects were arguments of discussion during the final round. Most experts believed that the power used is 3 W, but it can be increased up to 5 W to get a faster and possibly more effective treatment. In fact, while most studies reported a fixed 3 W power protocol [5,7–9], two studies explored the possibility to start with higher

power (4.5 5–W, then reduced to 3 W) that led to a reduction of mean operation time [1,6]. About this, one expert reported his personal experience using 7 W power, leading to a faster treatment without provoking discomfort to patients. Surely this suggestion will be topic of future studies. Another important aspect is the use of multiple needles or one needle per lobe. Sometimes the planning software (Echolaser Smart Interface, Elesta S. p.a, Calenzano, Italy) indicates to insert more needles to extend the treatment area, especially in large prostates and with a hyperplastic median lobe. After discussion about outcomes of the two alternatives, experts agreed on inserting more needles when the software recommended it even if it implies a higher procedural cost. In literature, authors' strategies are different: some authors prefer to use multiple laser fibers (up to five, two for each large lobe, and one in case of a hyperplastic median lobe) [1,6,9], other ones choose the pull-back technique to cover all target tissue [5,7,8], but no one reports to do multiple reinsertions of one single fiber. One aspect to consider is the anesthesiologic protocol. Experts agreed on performing local anesthesia of perineal superficial tissue and periprostatic anesthesia with lidocaine, while the use of sedatives is still controversial. In fact, some experts believe that a conscious sedation can reduce patient's discomfort, while others think that it is not needed due to low invasiveness and short procedural time. It must be said that most studies on the topic reported to have performed the procedure under conscious sedation by midazolam [6–9], but more studies are needed to establish a standardized anesthesiologic protocol.

Experts agreed that patients can be discharged 2–4 h after the procedure, despite most studies reported a hospitalization of 1–2 days [5–7,9]. Instead, there are two recent clinical trials in which patients have been safely discharged the same day of the treatment, if no complications occurred during the 2–3 h observation period [1,3,4].

Need for catheterization after the procedure was discussed during the final round. Strong agreement was reached on placing the catheter in both catheter and non-catheter-carrying patients in previous rounds, which is in accordance with most studies [1,6–9]. Nevertheless, literature reported also different possibilities. In particular, Pacella et al. [5] described the removal of the catheter after the procedure in patients without a long story of urinary retention and in non-catheter-carriers, with a very low rate of AUR. Moreover, a clinical trial was evaluating the possibility not to place the catheter in case of a spontaneous voiding after the procedure and a PVR of <500 mL [11]. Consequently, further studies are needed to highlight benefits and risks of not catheterizing patients who underwent Echolaser® TPLA.

Prolonging the antibiotic therapy started before the procedure and using corticosteroids and non-steroid anti-inflammatory drugs for anti-inflammatory and anti-edema purposes have been strongly recommended by the panel of experts in online rounds and suggested by literature [1,5–7,9]. Instead, the use of alpha-blockers was discussed in final round, concluding that it can help patients managing urinary symptoms until the effect of the treatment starts manifesting. Manenti et al. [1] described having continued them for 30 days after the procedure.

Safety of Ecolaser® TPLA was confirmed by both experts' experience and literature. In fact, published trials principally reported low-grade complications (Clavien-Dindo Grade I, such as dysuria and transient hematuria, only few cases of AUR and rare cases of high-grade complications (Clavien-Dindo Grade III, such as prostatic abscesses) [1,5–9].

Consensus was achieved on using IPSS, uroflowmetry parameters (maximum flow rate), and PVR as main parameters to define the efficacy of the treatment. As described in literature, their improvement can be observed as early as 1–3 months after the procedure [6,7,9] and tend to increase at 6 months [6,9]. As previously said, clinical studies reported preservation of anterograde ejaculation after the treatment and improvement in case of pre-procedural ejaculatory dysfunction [1,6,9]. Moreover, none of the studies reported urinary incontinence after the treatment [1,5–9]. Based on their experience, experts believed that transperineal approach is safer than transurethral or transrectal ones; comparative studies could highlight the differences between these approaches in terms of safety.

Strong agreement was reached on choosing organ sparing techniques like Ecolaser® TPLA rather than more aggressive treatment, when possible, because they can lead to satisfying functional outcomes minimizing treatment-related complications. Strong consensus was achieved on performing the procedure on low-risk PCa (GS <7), as shown in studies on transperineal FLA [12–15]. The treatment was also considered a promising option for intermediate-risk PCa (GS 7) [12–14]. According to an expert, an evaluation of cribriform component of GS 4 should be done to decide whether to perform the procedure or not in these cases. Instead, experts agreed not to use Ecolaser® TPLA for high-risk PCa (GS >7), in accordance with a Delphi consensus on FLA [16].

Lack of significant changes in IPSS, the 5-item version of the International Index of Erectile Function score, maximum flow rate, and PVR makes Ecolaser® TPLA a good alternative to radical prostatectomy in selected patients who have strong will to maintain urinary and sexual function [2]. Moreover, if performed also on transitional zone of the prostate, experts agreed that it can be a smart strategy to treat both PCa and BPH in patients with LUTS.

Agreement was reached on the possibility of performing the treatment in case of recurrence after transurethral procedures, but not after radical prostatectomy. Instead, an expert suggested its use in case of recurrence after external beam radiation based on its personal experience. Limitations on the use of FLA to target ablations and its performance on patients with short life expectancy were already discussed in a Delphi consensus on FLA [16] and our experts confirmed its results.

Recommendations on mpMRI, histological confirmation, and the need of systematic biopsies were in line with the results of the Delphi consensus for FLA [16]. In addition, our experts agreed that biopsies should be MRI/transrectal ultrasound fusion guided, as reported in the clinical study on Ecolaser® TPLA [2]. Experts confirmed that they can be autonomous during the procedure and they do not require a radiologist supporting them, in contrast on what reported in a study on a different FLA system [12]. Respecting ablation margin and using a fusion system during the treatment have

been considered important, based on their experience. Consensus was achieved on placing a catheter after the procedure in all patients. Regarding that, in clinical trial on Ecolaser® TPLA, the catheter was placed only in a patient with AUR immediately after the procedure; in the remaining patients, no catheter was used and no one developed AUR [2]. As for the treatment of BPH, the need of catheterization is worthy of further studies.

In accordance with the Delphi consensus for FLA, agreement was reached on using mpMRI for restaging, considering a residual GS 3+3 as a treatment success and evaluating it necessarily with mpMRI and random biopsies of the treated area [16]. In addition, our experts agreed on performing another treatment with Ecolaser® TPLA in case of recurrence, rather than moving on to more aggressive procedures. Consensus was reached on the safety of Ecolaser® TPLA. In fact, in clinical trial on Ecolaser® TPLA, only mild-moderate treatment-related complications (Common Terminology Criteria for Adverse Events 2) occurred, all spontaneously resolved or successfully treated [2]. Comparative studies on the approaches of FLA should be performed to underline their similarities and differences in terms of safety. As previously said, both ejaculatory function and external urethral sphincter function are well preserved by the treatment [2]; this represents an important advantage especially in young patients affected by PCa.

5. Limitations of the study

We acknowledge the limitations of the study. The panel of experts may not represent all urologists and radiologists performing treatments for BPH and PCa, so their opinion should not be referred to the entire community. There is a preponderance of responses from Italy rather than all other participants' countries. Furthermore, not all experts invited actually participated (response rate 77.5%–80.0%).

6. Conclusion

This paper includes the first consensus statements and recommendations on the use of Ecolaser® TPLA for the treatment of BPH and PCa. Our consensus project reflects the opinions of experts in the field and results can be used as guidelines and recommendations for urologists and radiologists performing Ecolaser® TPLA. Ecolaser® TPLA is confirmed as a safe procedure for the treatment of BPH and localized PCa, which can be performed in selected patients with good functional and sexual outcomes. Nevertheless, this project highlighted some areas where literature data are still inconclusive; in these cases, clinical experience has been the basis of experts' opinions, but the need of further studies is evident, especially to establish a standardized procedural protocol and to better assess the efficacy of the procedure.

Author contributions

Study concept and design: Andrea Cocci, Francesco Sessa, Andrea Minervini, Sergio Serni, Andrea Cocci, Fernando Bianco, Franco Blefari, Pierluigi Bove, Francois Cornud,

Gaetano De Rienzo, Paolo Destefanis, Danilo Di Trapani, Alessandro Giacobbe, Luca Giovanessi, Antonino Laganà, Giovanni Lughezzani, Guglielmo Manenti, Gianluca Muto, Gianluigi Patelli, Novello Pinzi, Stefano Regusci, Juan I. M. Salamanca, Matteo Salvi, Luigi Silvestri, Fabrizio Verweij, Eric Walser, Alessandro Bertaccini, Debora Marchiori, Hugo Davila, Pasquale Ditunno, Paolo Gontero, Gennaro Iapicca, Theo M De Reijke, Vito Ricapito, Pierluca Pellegrini, Francesco Sessa.

Data analysis: Andrea Cocci.

Drafting of manuscript: Marta Pezzoli.

Critical revision of the manuscript: Andrea Cocci, Francesco Sessa, Giorgio I. Russo, Riccardo G. Bertolo, Valerio Iacovelli.

Conflicts of interest

The authors declare no conflict of interest.

Appendix A. Supplementary data

Supplementary data to this article can be found online at <https://doi.org/10.1016/j.ajur.2023.07.001>.

References

- [1] Manenti G, Perretta T, Calcagni A, Ferrari D, Ryan CP, Fraioli F, et al. 3-T MRI and clinical validation of ultrasound-guided transperineal laser ablation of benign prostatic hyperplasia. *Eur Radiol Exp* 2021;5:41. <https://doi.org/10.1186/s41747-021-00239-9>.
- [2] van Riel LA, van Kollenburg RAA, Vis AN, van Leeuwen PJ, de Reijke TM, de Bruin DM, et al. Safety and feasibility of Soractelite transperineal focal laser ablation for prostate cancer and short-term quality of life analysis from a multicenter pilot study. *Eur Urol Open Sci* 2022;39:48–54.
- [3] Sessa F, Polverino P, Siena G, Bisegna C, Lo Re M, Spatafora P, et al. Transperineal laser ablation of the prostate (TPLA) for lower urinary tract symptoms due to benign prostatic obstruction. *J Clin Med* 2023;12:793. <https://doi.org/10.3390/jcm12030793>.
- [4] Sessa F, Polverino P, Bisegna C, Siena G, Lo Re M, Spatafora P, et al. Transperineal laser ablation of the prostate with EchoLaser™ system: perioperative and short-term functional and sexual outcomes. *Front Urol* 2022;2:969208. <https://doi.org/10.3389/fruro.2022.969208>.
- [5] Pacella CM, Patelli G, Iapicca G, Manenti G, Perretta T, Ryan CP, et al. Transperineal laser ablation for percutaneous treatment of benign prostatic hyperplasia: a feasibility study. Results at 6 and 12 months from a retrospective multi-centric study. *Prostate Cancer Prostatic Dis* 2020;23:356–63.
- [6] de Rienzo G, Lorusso A, Minafra P, Zingarelli M, Papapicco G, Lucarelli G, et al. Transperineal interstitial laser ablation of the prostate, a novel option for minimally invasive treatment of benign prostatic obstruction. *Eur Urol* 2021;80:95–103.
- [7] Patelli G, Ranieri A, Paganelli A, Mauri G, Pacella CM. Transperineal laser ablation for percutaneous treatment of benign prostatic hyperplasia: a feasibility study. *Cardiovasc Intervent Radiol* 2017;40:1440–6.
- [8] Cai HJ, Fang JH, Kong FL, Xu CK, Chen CH, Wang W, et al. Ultrasound-guided transperineal laser ablation for percutaneous treatment of benign prostatic hyperplasia: a new minimally invasive interventional therapy. *Acta Radiol* 2021;63:553–8.
- [9] Frego N, Saita A, Casale P, Diana P, Contieri R, Avolio PP, et al. Feasibility, safety, and efficacy of ultrasound-guided transperineal laser ablation for the treatment of benign prostatic hyperplasia: a single institutional experience. *World J Urol* 2021;39:3867–73.
- [10] Hsu CC, Sandford BA. The Delphi technique: making sense of consensus. *Practical Assess Res Eval* 2007;12. <https://doi.org/10.7275/pdz9-th90>.
- [11] van Kollenburg RAA, van Riel LAMJG, Bloemen PR, Oddens JR, de Reijke TM, Beerlage HP, et al. Transperineal laser ablation treatment for lower urinary tract symptoms due to benign prostatic obstruction: protocol for a prospective *in vivo* pilot study. *JMIR Res Protoc* 2020;9:e15687. <https://doi.org/10.2196/15687>.
- [12] Mehrlivand S, George AK, Hoang AN, Rais-Bahrami S, Rastinehad AR, Lebastchi AH, et al. MRI-guided focal laser ablation of prostate cancer: a prospective single-arm, single-center trial with 3 years of follow-up. *Diagn Interv Radiol* 2021;27:394–400.
- [13] Eggener SE, Yousuf A, Watson S, Wang S, Oto A. Phase II evaluation of magnetic resonance imaging guided focal laser ablation of prostate cancer. *J Urol* 2016;196:1670–5.
- [14] Oto A, Sethi I, Karczmar G, McNichols R, Ivancevic MK, Stadler WM, et al. MR imaging-guided focal laser ablation for prostate cancer: phase I trial. *Radiology* 2013;267:932–40.
- [15] Barqawi A, Krughoff K, Li H, Patel NU. Initial experience of targeted focal interstitial laser ablation of prostate cancer with MRI guidance. *Curr Urol* 2015;8:199–207.
- [16] van Luijckelaar A, Greenwood BM, Ahmed HU, Barqawi AB, Barret E, Bomers JGR, et al. Focal laser ablation as clinical treatment of prostate cancer: report from a Delphi consensus project. *World J Urol* 2019;37:2147–53.