

# Trifocal versus monofocal intraocular lens implantation in eyes previously treated with laser in situ keratomileusis (LASIK) for myopia

Rafael Bilbao-Calabuig<sup>1</sup>, Julio Ortega-Usobiaga<sup>2</sup>, Fernando Mayordomo-Cerdá<sup>3</sup>, Jaime Beltrán-Sanz<sup>4</sup>, Javier Fernández-García<sup>3</sup>, Rosario Cobo-Soriano<sup>1,5</sup>

**Purpose:** To assess visual and refractive outcomes of trifocal intraocular lens (IOL) implantation in eyes that had previously undergone laser *in situ* keratomileusis (LASIK) for myopia and to compare them with those recorded after implantation of a monofocal IOL. **Design:** Retrospective comparative cases series. **Methods:** This study evaluated uncorrected distance visual acuity (UDVA), corrected distance visual acuity (CDVA), uncorrected near visual acuity (UNVA), safety, and efficacy after the implantation of two comparable trifocal IOL models and one monofocal IOL model in patients who had previously undergone myopic LASIK. Patients were classified according to the implanted IOL (monofocal or trifocal). **Results:** A total of 211 eyes from 170 patients received a monofocal IOL, and 211 eyes from 161 patients received a trifocal IOL. At the end of the study, after lensectomy, there was a higher myopic residual spherical equivalent in the monofocal group because some eyes had been targeted for slight myopia to achieve monovision; therefore, UDVA was better in the trifocal group. CDVA was comparable in both groups. As expected, both monocular and binocular UNVA were significantly better in the trifocal group. Although the percentage of eyes that lost  $\geq 1$  line of CDVA did not differ between the groups, the safety index was slightly better in the monofocal group. **Conclusion:** Although implantation of monofocal and trifocal IOLs after myopic LASIK yielded excellent distance visual outcomes, UNVA was significantly better for the trifocal IOL, with a minimally worse safety profile. Trifocal IOLs can be considered after previous LASIK for myopia, with an appropriate patient selection.

**Key words:** Laser visual correction, LASIK, multifocal intraocular lens, myopia, PRK, trifocal intraocular lens

During the last 30 years, millions of patients have undergone corneal laser vision correction (LVC), encouraged by the excellent refractive and satisfaction outcomes obtained, especially for the treatment of myopia. With aging, many of these patients develop presbyopia or cataract and wish to maintain their spectacle independence. Improvements in surgical techniques and intraocular lens (IOL) designs have achieved that replacing an aged dysfunctional crystalline lens leads to stable and functional uncorrected near, intermediate, and distance visual acuity (UNVA, UIVA, and UDVA). A systematic review of the medical literature,<sup>[1]</sup> confirmed that bilateral implantation of multifocal (MF) IOLs obtains good results for distance and near visual acuity and improves the independence of glasses compared to monofocal IOLs. However, these IOLs have certain drawbacks as halos and reflections and poorer contrast sensitivity, especially under low lighting conditions, are more frequent than with monofocal IOLs.<sup>[2]</sup> Initially, previous corneal LVC was considered a relative contraindication for MF IOL implantation<sup>[3]</sup> for several

reasons. First, the LVC corneas were considered multifocal and aberrated after the ablation, with the potential to decrease multifocal IOL visual performance, especially under mesopic conditions. Second, IOL power calculations in these eyes remain challenging, even though sources of biometric errors are well established; and achieving emmetropia is especially important to obtain a spectacle-free vision with MF IOLs. Finally, after MF IOL implantation, patients may require further laser excimer treatment to correct any residual refractive error, and this could be limited in cases with extensive previous LVC or insufficient corneal thickness. As these factors can deteriorate the quality of vision, lens surgery with implantation of a multifocal IOL remains a controversial issue in these patients despite our extensive knowledge of and experience in both corneal and lens surgical techniques.

Some studies with small series of cases have shown optimal visual and refractive outcomes with hybrid diffractive-

This is an open access journal, and articles are distributed under the terms of the Creative Commons Attribution-NonCommercial-ShareAlike 4.0 License, which allows others to remix, tweak, and build upon the work non-commercially, as long as appropriate credit is given and the new creations are licensed under the identical terms.

**For reprints contact:** WKHLRPMedknow\_reprints@wolterskluwer.com

**Cite this article as:** Bilbao-Calabuig R, Ortega-Usobiaga J, Mayordomo-Cerdá F, Beltrán-Sanz J, Fernández-García J, Cobo-Soriano R. Trifocal versus monofocal intraocular lens implantation in eyes previously treated with laser in situ keratomileusis (LASIK) for myopia. *Indian J Ophthalmol* 2024;72:S254-9.

#### Access this article online

##### Website:

<https://journals.lww.com/ijo>

##### DOI:

10.4103/IJO.IJO\_1844\_23

#### Quick Response Code:



<sup>1</sup>Department of Cataract and Refractive Surgery, Clínica Baviera (Aier Eye Hospital Group), Madrid, <sup>2</sup>Department of Cataract and Refractive Surgery, Clínica Baviera (Aier Eye Hospital Group), Bilbao, <sup>3</sup>Department of Cataract and Refractive Surgery and <sup>4</sup>Research and Development, Clínica Baviera (Aier Eye Hospital Group), Valencia, <sup>5</sup>Francisco de Vitoria University, Madrid, Spain

**Correspondence to:** Dr. Julio Ortega-Usobiaga, Clínica Baviera, Ibanex de Bilbao, 9. 48009 Bilbao, Spain. E-mail: jortega@clinicabaviera.com

Received: 13-Jul-2023

Revision: 23-Oct-2023

Accepted: 31-Oct-2023

Published: 25-Jan-2024

refractive<sup>[4-6]</sup> and low addition diffractive extended-range of vision (EDOF)<sup>[7]</sup> IOLs in patients with previous corneal LVC for myopia. Recent clinical studies and systematic reviews have demonstrated the advantages of trifocal IOLs over their predecessor bifocal diffractive IOLs.<sup>[8,9]</sup> Nowadays, diffractive trifocal IOLs offer the highest rates of spectacle independence outcomes among currently available lenses after cataract and refractive lens exchange (RLE), and trifocal IOLs may currently be the most widely implanted type of IOL for presbyopia correction.<sup>[10]</sup> Therefore, they could become a very interesting and reliable option for patients with previous myopic LVC.

The primary objective of the current study was to evaluate, in a large cohort of patients, visual and refractive outcomes of trifocal IOL implantation in eyes previously treated with LVC for myopia. The secondary goal was to compare these clinical outcomes with those obtained with monofocal IOLs, especially in terms of safety.

## Methods

### Design

This multicenter, multisurgeon, single-protocol, retrospective, comparative case series study comprised consecutive eyes previously treated with LVC for myopia at our institution that underwent lensectomy (both for cataract and RLE) with a trifocal or monofocal IOL implantation. The lens procedures were performed at Clinica Baviera Spain from 2015 to 2019.

### Subjects

Data were recorded from the central computerized clinical records system at Clinica Baviera Spain. The study was approved by our institutional legal and ethics committee. All patients received detailed information before surgery and provided their specific written informed consent for RLE or cataract surgery after corneal LVC with either a non-toric trifocal or a monofocal IOL implant and for the use of their anonymous and aggregated medical data for clinical research.

Exclusion criteria were (a) eyes with subnormal optics, such as small optical zones, decentered ablations, and deep amblyopia or low vision (preoperative corrected distance visual acuity [CDVA] <0.3 decimal); (b) eyes with any significant baseline anatomical abnormality (anterior or posterior segment); (c) any significant perioperative complication (during corneal LVC and/or lensectomy); and (d) eyes with pre-lensectomy keratometric cylinder >1.50 diopters (D).

### Clinical evaluation

Both surgical procedures (LVC and lensectomy) were performed at our institution and involved similar preoperative assessments. All patients underwent a comprehensive ophthalmologic examination that included refractive and visual acuity data (uncorrected and corrected, and manifest and cycloplegic), topography, slit-lamp biomicroscopy, ocular surface/tear film evaluation, and fundoscopy. Different corneal topography devices were used at different times during the study period, as follows: Orbscan II (Bausch and Lomb, Rochester, NY, USA), Pentacam (HR, Oculus Optikgerate, GmbH, Wetzlar, Germany), and the Wavelight-Oculyzer (Alcon Laboratories, Fort Worth, TX, USA).

Preoperative examination for lensectomy also included endothelial cell count (SP 3000P; Topcon, Capelle, Netherlands)

and macular optical coherence tomography (SOCT Copernicus-REVO, Optopol-Tech, Zawiercie, Poland). Biometry data were obtained using partial coherence interferometry (IOLMaster; Carl-Zeiss-Meditec AG, Jena, Germany). The IOL power calculation was performed using the American Society of Cataract and Refractive Surgery (ASCRS) calculator, with the preferred formula and the searched refractive result selected by each surgeon in each case. Some eyes in the monofocal group were targeted for a minor myopic residual result (-1 D to -1.5 D) in an attempt to achieve monovision, whereas eyes implanted with trifocal IOL were targeted for emmetropia.

### Intraocular lenses

The type of IOL selection was based on the surgeon's choice, the patient's preferences based on each clinical case's features, and the IOL model availability at each surgical center.

The diffractive trifocal IOLs implanted during the study period were the FineVision Micro-F and the FineVision Pod-F (BVI-PhysIOL, Liège, Belgium). Both IOLs are made of foldable hydrophilic acrylic material. The FineVision Micro-F (single-piece, tetraloop lens) and the FineVision Pod-F (single-piece, double C-loop lens) combine two diffractive structures adjusted to offer a +3.5-D addition for near vision and a +1.75-D addition for intermediate vision; both have a moderate negative aspheric profile of -0.11  $\mu\text{m}$ . The monofocal aspheric IOL implanted was the Micropure (BVI-PhysIOL, Liège, Belgium), a foldable hydrophobic glistening-free, single-piece, tetraloop lens.

### Surgical procedures

Both the LVC and the lens surgical procedures were performed by experienced surgeons with a single pre- and postoperative protocol. Corneal LVC was performed by laser *in situ* keratolysis (LASIK). LASIK was performed with two microkeratomers with nasal hinges (Moria LSK-ONE and Moria ONE-USE-PLUS-SBK, Microtech Inc., Moria Ophthalmic Instruments, Anthony, France) and three excimer laser models, namely the Technolas 217C, 217-Z-100 (Bausch and Lomb, Claremont, CA, USA), the Mel-80 (Carl Zeiss Meditec, Jena, Germany), and the WaveLight-Allegretto Wave-Eye-Q (Alcon Laboratories, Fort Worth, TX, USA).

Patients returned because of a reduction in UDVA, UNVA, or both (cataracts and/or presbyopia).

Standard uneventful clear corneal incision phacoemulsification was performed with the implantation of a monofocal or trifocal IOL in the capsular bag.

When a secondary corneal laser enhancement was needed after lensectomy (bioptics), this was performed using an alcohol-assisted photorefractive keratectomy (PRK) technique.

### Refractive and visual measures

Refractive and visual outcomes were obtained from the last available visit, with at least 3 months of follow-up after lensectomy. Visual results included average logMAR UDVA, CDVA, and UNVA and refractive data (sphere, cylinder, manifest refractive spherical equivalent [MRSE], and accuracy (percentage of eyes within  $\pm 0.25$  D,  $\pm 0.50$  D, and  $\pm 1.0$  D]). Change in CDVA between post-LASIK versus post-lensectomy was calculated to measure safety

outcomes (percentage of eyes with loss of  $\geq 1$  and  $\geq 2$  lines of Snellen CDVA). Efficacy outcomes were calculated as the percentage of eyes with a difference between post-lensectomy UDVA and post-LASIK CDVA  $\geq 0$  lines). We decided to compare post-lensectomy/post-LASIK changes in visual acuity instead of between post-lensectomy/pre-lensectomy changes because the pre-lensectomy UDVA and CDVA were distorted by the variable degree of anatomical lens opacity, and the aim of this study was to measure functional results derived from the interaction between a multifocal IOL with an aberrated cornea, without interference from the opacified crystalline lens. Refractive results and predictability are not fully comparable between the groups because in the case of monofocal IOLs, some eyes were targeted for a final  $-1.00$  D to  $-1.50$  D spherical equivalent in a monovision strategy.

In addition, we measured the percentage of corneal laser enhancement for residual refraction after lensectomy (bioptics procedure).

### Statistical analysis

The statistical analysis was performed using R Development Core Team (2008). After analyzing the distribution of the variables, we adopted a robust approach to describe data and test the differences in mean values. We reported ranges and trimmed means with winsorized standard deviations by using 20% winsorization as suggested by Wilcox (2011). To compare winsorized means, we performed Yuen test as described in Wilcox. When comparing discrete variables, we applied either the Chi-square test or Fisher's exact test, depending on the distribution of the expected frequencies. Differences were considered to be statistically significant when the  $P$  value was  $< 0.05$ . Standardized graphics for refractive surgery and lens-based refractive surgery were provided.<sup>[11]</sup>

## Results

A monofocal IOL was implanted in 211 eyes from 170 patients, and a trifocal IOL was implanted in 211 eyes from 161 patients. The diffractive trifocal IOLs implanted during the study period were the FineVision Micro-F in 180 eyes (85%) eyes and the FineVision Pod-F in 31 eyes (15%). Demographic data are shown in Table 1.

The mean time elapsed between the corneal LVC and implantation of the IOL was 12.4 years (range: 5-20 years). All patients completed a minimum of 3-month postoperative follow-up after lens surgery; the median follow-up was 5 months (mean:  $5.12 \pm 2.4$ ; range: 3–13 months).

Refractive data are displayed in Table 2. Mean pre and post-LVC refractive and visual results were comparable in

**Table 1: Demographic data**

	Monofocal Group	Trifocal Group	P
Eyes	211	211	
Patients	170	161	
Females (%)	76 (44.71%)	71 (44.1%)	1.000*
Males (%)	94 (55.29%)	90 (55.9%)	
Age (years) $\pm$ SD	$56.42 \pm 5.37$	$55.38 \pm 4.13$	0.238**

\*Chi-Square test. \*\*Yuen test for trimmed means of independent samples. SD: Standard deviation

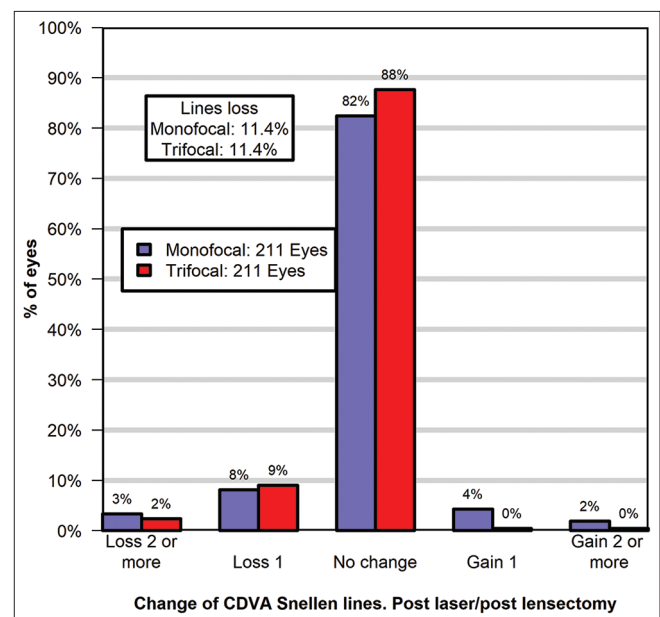
both groups. Before lensectomy, significantly worse UDVA and CDVA and higher MRSE were present in the monofocal group, probably related to an average denser preoperative lens opacity in this group. After lensectomy, there was a previously mentioned higher myopic residual MRSE in the monofocal group that resulted in a worse UDVA in this group. However, CDVA was equivalent in both groups.

Both monocular and binocular UNVA were significantly better in the trifocal group.

Table 3 and Fig. 1 show post-lensectomy safety and predictability results between post LVC and post lensectomy. There were no differences between the proportion of eyes with no change or gain of  $\geq 1$  line of CDVA (88.57%), and the proportion of eyes with loss of  $\geq 1$  line (11.43%) in both groups [Fig. 1]. However, the safety index was minimally better in the monofocal group [Table 3]. Post lensectomy, in the trifocal group, 65% of eyes were between  $\pm 0.50$  D and 87% between  $\pm 1.00$  D from emmetropia. In the monofocal group, 47% of eyes were between  $\pm 0.50$  D and 66% between  $\pm 1.00$  D. As mentioned previously, some eyes in the monofocal group were targeted for a minor myopic residual result, whereas eyes implanted with trifocal IOL were targeted for emmetropia. Therefore, predictability outcomes were not comparable between both groups. The rate of corneal laser enhancement after the lens procedure was significantly higher in the trifocal group (15.2% vs. 8.5%).

## Discussion

Patients with a successful previous corneal LVC, with high expectations and motivation for spectacle independence, are more likely to request a new surgical intervention when they develop presbyopia or cataract. However, the decision to implant a multifocal IOL in these patients remains controversial. Cataract surgery and RLE, with implantation of a trifocal IOL, provide good functional UDVA, UIVA, and UNVA, with a high level of spectacle independence and patient



**Figure 1: Safety in the monofocal IOL group and the trifocal IOL group (after LVC vs. after lensectomy): change in CDVA lines**

**Table 2: Evolution of refractive and visual data of monofocal and trifocal IOL groups at laser visual correction (LVC) surgery, post-LVC, pre- and post-lensectomy periods**

	Monofocal Group (n=211 eyes)	Trifocal Group (n=211 eyes)	P
Primary refractive data: Mean±SD (Range)			
Pre-LVC CDVA (logMAR)	0.02±0.04 (0.00/0.52)	0.03±0.04 (0.00/0.46)	0.590*
Sphere (D) <sup>a</sup>	-3.46±1.54 (-10.00/+0.50)	-3.29±1.26 (-10.25/+0.50)	0.491*
Cylinder (D) <sup>a</sup>	-0.91±0.57 (-4.25/0.00)	-0.91±0.58 (-4.00/0.00)	0.973*
MRSE laser (D) <sup>a</sup>	-3.97±1.45 (-10.62/-0.38)	-3.77±1.28 (-10.75/-0.50)	0.419*
POST-LVC DATA: Mean±SD (Range)			
Sphere (D)	-0.12±0.28 (-2.25/+0.75)	-0.17±0.31 (-3.50/+0.75)	0.372*
Cylinder (D)	-0.3±0.28 (-1.50/0.00)	-0.26±0.24 (-1.50/0.00)	0.422*
MRSE (D)	-0.27±0.34 (-2.25/+0.75)	-0.31±0.35 (-3.50/+0.75)	0.442*
Post-LVC UDVA (logMAR)	0.06±0.07 (0.00/0.80)	0.04±0.06 (0.00/0.90)	0.090*
Post-LVC CDVA (logMAR)	0.01±0.03 (0.00/0.40)	0.01±0.02 (0.00/0.40)	0.265*
Pre-lensectomy data: Mean±SD (Range)			
MRSE (D)	-2.09±1.71 (-12.00/+5.00)	-1.17±1.45 (-10.00/+3.50)	<0.001*
Cylinder (D)	-0.63±0.46 (-1.50/0.00)	-0.5±0.39 (-1.50/0.00)	0.067*
UDVA (logMAR)	0.63±0.41 (0.00/1.00)	0.42±0.35 (0.00/1.00)	<0.001*
DCVA (logMAR)	0.24±0.13 (0.00/1.00)	0.11±0.10 (0.00/1.00)	<0.001*
UNVA (logMAR)	0.27±0.15 (0.00/1.00)	0.35±0.26 (0.00/1.00)	<0.001*
AXL (mm)	25.67±0.88 (20.21/33.83)	25.18±0.78 (22.33/31.41)	<0.001*
Post-lensectomy final visual and refractive outcomes			
Post-lensectomy UDVA <sup>b</sup>	0.16±0.15 (0.00/0.80)	0.09±0.07 (0.00/0.40)	<0.001*
Post-lensectomy CDVA (logMAR) <sup>b</sup>	0.03±0.04 (0.00/0.20)	0.04±0.04 (0.00/0.20)	0.099*
Post-lensectomy UNVA (logMAR) <sup>b</sup>	0.34±0.16 (0.10/0.90)	0.14±0.07 (0.00/0.30)	<0.001*
Post-lensectomy binocular UNVA (logMAR) <sup>b</sup>	0.18±0.09 (0.10/0.90)	0.09±0.07 (0.00/0.20)	<0.001*
Post-lensectomy MRSE (D) <sup>b</sup>	-0.65±0.53 (-2.88/+1.12)	-0.29±0.29 (-1.15/+1.25)	<0.001*
Post-lensectomy cylinder (D) <sup>b</sup>	-0.45±0.36 (-1.50/0.00)	-0.30±0.31 (-1.00/0.00)	0.004*

SD: Standard deviation. MRSE: manifest refraction spherical equivalent. <sup>a</sup>LVC refraction. <sup>b</sup>Post-lensectomy final visual outcomes at the last available visit. UNVA: uncorrected distance visual acuity. UDVA: uncorrected distance visual acuity. CDVA: corrected distance visual acuity. \*Yuen test for trimmed means of independent samples

**Table 3: Monofocal versus Trifocal IOLs**

Post lensectomy	Monofocal Group (n=211 eyes)	Trifocal Group (n=211 eyes)	P
Safety (No change or ≥ 1 line gain) (%)	88.57%	88.57%	1.000*
Safety index (mean±SD) (post-lensectomy CDVA/post-LVC CDVA)	0.98 (±0.05)	0.96 (±0.06)	0.014**
Efficacy index (mean±SD) (post-lensectomy UDVA/post-LVC CDVA)	0.77 (±0.21)	0.86 (±0.12)	0.002**
Predictability (% eyes±0.5D)	47%	65%	<0.001*
Corneal laser enhancement after lensectomy (%)	8.53%	15.17%	<0.001*

Post-lensectomy safety, efficacy, and predictability. \*Chi-Square test. \*\*Yuen test for trimmed means of independent samples. SD: standard deviation. CDVA: Corrected distance visual acuity, UDVA: Uncorrected distance visual acuity. LVC: Laser visual correction

satisfaction.<sup>[12]</sup> Our broad experience and confidence with these IOLs have led us to gradually extend the implantation of trifocal IOLs in patients previously treated with LASIK.

However, the performance of trifocal IOLs after corneal LVC has not been widely studied, and published evidence is somehow still scarce. One retrospective series evaluated the visual outcomes of 20 eyes from 13 patients who had previously undergone LVC for myopia and subsequently received the AT LISA tri839MP trifocal IOL.<sup>[13]</sup> Favorable visual outcomes were recorded for both near and distance vision, although the outcome was more predictable for near

than for distance vision. A significant postoperative myopic shift was found (-0.92 ± 0.76 D), with 5% of patients reporting significant positive dysphotopic symptoms (halos and glare), and only 50% of patients achieved complete spectacle independence. Brenner *et al.* recently evaluated these IOLs in RLE after previous myopic and hyperopic LVC,<sup>[14]</sup> finding that implantation of trifocal IOLs was safe and effective in selected cases and that the use of optimized constants and nomogram could improve refractive accuracy.

A retrospective comparative study by our group compared the visual and refractive outcomes of trifocal IOLs in eyes

previously treated with LVC for myopia and hyperopia.<sup>[15]</sup> In the myopia group (319 eyes), patients achieved good visual outcomes, although predictability was lower in the high myopia subgroup. Another recent retrospective study, also by our group, evaluated the impact of corneal spherical aberration on the postoperative visual outcomes of trifocal IOLs in eyes previously treated with LVC for myopia and hyperopia.<sup>[16]</sup> It was concluded that surgeons should consider tomographic corneal spherical aberration to prevent vision loss after lensectomy, particularly in eyes previously treated for hyperopia.

In the present study comparing two groups implanted with either a trifocal or a monofocal IOL, both types of IOLs yielded excellent CDVA. The safety index was 0.96 for trifocal IOLs and 0.98 for monofocal IOLs, indicating that lens surgery in myopic eyes previously treated with LVC is a safe procedure for both types of IOLs. Nevertheless, monofocal IOLs show a statistically significant but minimally safer profile. At least 1 line of CDVA was lost in 11.4% of eyes in both groups. This difference was not statistically significant. The results are in accordance with those found by Brenner *et al.*,<sup>[14]</sup> who reported a 0.97 safety index in the myopic ablation group implanted with the trifocal IOL.

Although distance visual outcomes were optimal in both groups, considering uncorrected near vision, the binocular and monocular results obtained with the trifocal IOL were significantly better. If we had recorded satisfaction results with a validated questionnaire, then this finding may have reflected better spectacle independence for the trifocal group.

Postoperative visual outcomes in patients who received a trifocal IOL in this study are comparable to those obtained in post-myopic LVC patients in a recent study by Cobo-Soriano *et al.*<sup>[15]</sup> in a subgroup of 319 eyes with a mean MRSE of  $-3.32$  D before LVC. After implantation of the trifocal IOL, their mean postoperative CDVA and mean UDVA were  $0.03 \pm 0.04$  logMAR and  $0.09 \pm 0.08$  logMAR, respectively. In our study, CDVA was  $0.04 \pm 0.04$  and UDVA was  $0.09 \pm 0.07$ . These results emphasize the positive visual outcomes obtained with this refractive strategy.

Our results for the trifocal group are comparable to those found in studies with the implantation of trifocal IOL in patients who had not previously undergone corneal LVC. In 2017, our group reported results for a large series comprising over 10,000 eyes with non-operated corneas after implantation of the same trifocal IOL model.<sup>[12]</sup> After surgery, the mean CDVA was  $0.03 \pm 0.06$  logMAR and the mean UDVA was  $0.06 \pm 0.08$  logMAR.

The laser enhancement rate was significantly higher in the trifocal group than in the monofocal IOL group (15.2% and 8.5%, respectively). These data confirm that implantation of a trifocal IOL requires greater refractive accuracy as it is less tolerant to residual ametropia than monofocal IOLs, with or without a monovision strategy. This issue is especially relevant in eyes that have previously undergone LVC in which induced corneal aberrations could further decrease postoperative tolerance of residual ametropia. Furthermore, these results emphasize the need to adequately address the IOL calculation by means of accurate preoperative biometric measurements and appropriate selection of formulas, as well

as the importance of considering the need for a new eventual laser enhancement, possibly with a greater risk than in patients with naïve corneas who receive trifocal IOLs. Such an approach includes a thorough preoperative assessment of the residual corneal thickness and the approximate amount of the initial laser photoablation.

LVC modifies the shape of the anterior corneal surface, thus inducing a positive spherical aberration after treatment for myopia. Although the study did not evaluate ocular aberrations, implanting aspherical IOLs with a negative spherical aberration, both for monofocal and diffractive trifocal IOLs, as was the case with all the implanted models in our series, may have compensated—at least partially—for the laser-induced positive spherical aberration of the corneas, thus potentially minimizing further deterioration in optical quality and CDVA after implantation of the trifocal IOLs.

The current study is subject to a series of limitations. First, it is retrospective and includes data gathered from multiple surgical centers. However, surgeons and optometrists from all the centers followed the same patient management protocol. Second, patient satisfaction and visual quality could not be assessed using a subjective or objective measurement, which could have provided us with valuable information about spectacle independence and visual quality. We currently administer a postoperative questionnaire to all patients receiving a trifocal IOL but do not do so in patients who receive monofocal IOLs. Consequently, satisfaction could not be appropriately compared.

## Conclusion

In summary, our study shows that distance visual outcomes are excellent with both monofocal and trifocal IOLs after LASIK for myopia. UNVA was significantly better with the trifocal implant. However, this expected improvement in patient's spectacle independence was obtained with a minimally worse safety profile. After previous LVC for myopia, implantation of a trifocal IOL is a very reasonable option, especially when appropriate preoperative selection is performed. Patients with preexisting highly aberrated corneas, patients with previous extensive laser photoablation, and patients for whom further laser enhancement may be compromised could be better candidates for implantation of an aspheric monofocal IOL, or an enhanced monofocal IOL with a negative spherical aberration profile.

**Financial support and sponsorship:** Nil.

**Conflicts of interest:** No conflicting financial interest in any of the products mentioned exists for any author. Rafael Bilbao-Calabuig is a medical advisor for BVI-Physiol.

## References

1. de Vries NE, Nuijts RM. Multifocal intraocular lenses in cataract surgery: Literature review of benefits and side effects. *J Cataract Refract Surg* 2013;39:268-78.
2. de Silva SR, Evans JR, Kirithi V, Ziaei M, Leyland M. Multifocal versus monofocal intraocular lenses after cataract extraction. *Cochrane Database Syst Rev* 2016;12:CD003169.
3. Braga-Mele R, Chang D, Dewey S, Foster G, Henderson BA, Hill W, *et al.* Multifocal intraocular lenses: Relative indications and contraindications for implantation. *J Cataract Refract Surg* 2014;40:313-22.
4. Muftuoglu O, Dao L, Mootha VV, Verity SM, Bowman RW, Cavanagh HD,

- et al.* Apodized diffractive intraocular lens implantation after laser *in situ* keratomileusis with or without subsequent excimer laser enhancement. *J Cataract Refract Surg* 2010;36:1815-21.
5. Alfonso JF, Madrid-Costa D, Poo-Lopez A, Montes-Mico R. Visual quality after diffractive intraocular lens implantation in eyes with previous myopic laser *in situ* keratomileusis. *J Cataract Refract Surg* 2008;34:1848-54.
  6. Fernandez-Vega L, Madrid-Costa D, Alfonso JF, Montés-Micó R, Poo-López A. Optical and visual performance of diffractive intraocular lens implantation after myopic laser *in situ* keratomileusis. *J Cataract Refract Surg* 2009;35:825-32.
  7. Ferreira TB, Pinheiro J, Zabala L, Ribeiro FJ. Comparative analysis of clinical outcomes of a monofocal and an extended-range-of-vision intraocular lens in eyes with previous myopic laser *in situ* keratomileusis. *J Cataract Refract Surg* 2018;44:149-55.
  8. Bilbao-Calabuig R, Gonzalez-Lopez F, Amparo F, Alvarez G, Patel SR, Llovet-Osuna F. Comparison between mix-and-match implantation of bifocal intraocular lenses and bilateral implantation of trifocal intraocular lenses. *J Refract Surg* 2016;32:659-63.
  9. Yoon CH, Shin IS, Kim MK. Trifocal versus bifocal diffractive intraocular lens implantation after cataract surgery or refractive lens exchange: A meta-analysis. *J Korean Med Sci* 2018;33:e275.
  10. Rodov L, Reitblat O, Levy A, Assia EI, Kleinmann G. Visual outcomes and patient satisfaction for trifocal, extended depth of focus and monofocal intraocular lenses. *J Refract Surg* 2019;35:434-40.
  11. Reinstein DZ, Waring GO 3<sup>rd</sup>. Graphic reporting of outcomes of refractive surgery. *J Refract Surg* 2009;25:975-8.
  12. Bilbao-Calabuig R, Llovet-Rausell A, Ortega-Usobiaga J, Martínez-Del-Pozo M, Mayordomo-Cerdá F, Segura-Albentosa C, *et al.* Visual outcomes following bilateral Implantation of two diffractive trifocal intraocular lenses in 10 084 eyes. *Am J Ophthalmol* 2017;179:55-66.
  13. Chow SSW, Chan TCY, Ng ALK, Kwok AKH. Outcomes of presbyopia-correcting intraocular lenses after laser *in situ* keratomileusis. *Int Ophthalmol*. 2019;39:1199-204.
  14. Brenner LF, Gjerdrum B, Aakre BM, Lundmark PO, Nistad K. Presbyopic refractive lens exchange with trifocal intraocular lens implantation after corneal laser vision correction: Refractive results and biometry analysis. *J Cataract Refract Surg* 2019;45:1404-15.
  15. Cobo-Soriano R, Ortega-Usobiaga J, Rodriguez-Gutierrez B, Tejerina V, Llovet F, Casco B, *et al.* Trifocal intraocular lens implantation in eyes with previous corneal refractive surgery for myopia and hyperopia. *J Cataract Refract Surg* 2021;47:1265-72.
  16. Cobo-Soriano R, Rodriguez-Gutierrez B, Bilbao-Calabuig R, Tejerina V, Fernández-Corrochano A, Druchkiv V, *et al.* Trifocal IOL implantation in eyes with previous laser corneal refractive surgery: The impact of corneal spherical aberration on postoperative visual outcomes. *J Refract Surg* 2022;38:222-8.