

THE PRESENT AND FUTURE

JACC REVIEW TOPIC OF THE WEEK

Histological Typing in Patients With Cardiac Amyloidosis



JACC Review Topic of the Week

Esther Gonzalez-Lopez, MD, PhD,^{a,b} Ellen D. McPhail, MD,^c Clara Salas-Anton, MD,^{b,d} Fernando Dominguez, MD, PhD,^{a,b} Morie A. Gertz, MD,^e Angela Dispenzieri, MD,^{c,e} Surendra Dasari, PhD,^f Paolo Milani, MD, PhD,^{g,h} Laura Verga, DVM, PhD,^{g,h} Martha Grogan, MD,ⁱ Giovanni Palladini, MD, PhD,^{g,h} Pablo Garcia-Pavia, MD, PhD^{a,b,j,k}

ABSTRACT

Cardiac amyloidosis is increasingly recognized as a treatable form of heart failure. Highly effective specific therapies have recently become available for the 2 most frequent forms of cardiac amyloidosis: immunoglobulin light chain amyloidosis and transthyretin (ATTR) amyloidosis. Nevertheless, initiation of specific therapies requires recognition of cardiac amyloidosis and appropriate characterization of the amyloid type. Although noninvasive diagnosis is possible for ATTR cardiac amyloidosis, histological demonstration and typing of amyloid deposits is still required for a substantial number of patients with ATTR and in all patients with light chain amyloidosis and other rarer forms of cardiac amyloidosis. Amyloid histological typing can be performed using different techniques: mass spectrometry, immunohistochemistry, and immunoelectron microscopy. This review describes which patients require histological confirmation of cardiac amyloidosis along with when and how to type amyloid deposits in histologic specimens. Furthermore, it covers the characteristics and limitations of the different typing methods that are available in clinical practice. (J Am Coll Cardiol 2024;83:1085-1099) © 2024 The Authors. Published by Elsevier on behalf of the American College of Cardiology Foundation. This is an open access article under the CC BY-NC-ND license (<http://creativecommons.org/licenses/by-nc-nd/4.0/>).

Cardiac amyloidosis (CA) is a progressive, often fatal disease, increasingly recognized as a cause of heart failure and in other common clinical scenarios like severe aortic stenosis and unexplained left ventricular hypertrophy.¹⁻⁶

According to the International Society of Amyloidosis, to date, more than 40 proteins are known to form amyloid but just 10 of them produce significant cardiac deposition, resulting in CA¹ (Table 1). Although light chain amyloidosis (AL) and



Listen to this manuscript's audio summary by Editor-in-Chief Dr Valentin Fuster on www.jacc.org/journal/jacc.

From the ^aDepartment of Cardiology, Hospital Universitario Puerta de Hierro Majadahonda, IDIPHISA, Madrid, Spain; ^bCIBER Cardiovascular, Instituto de Salud Carlos III, Madrid, Spain; ^cDepartment of Laboratory Medicine and Pathology, Mayo Clinic, Rochester, Minnesota, USA; ^dDepartment of Pathology, Hospital Universitario Puerta de Hierro Majadahonda, IDIPHISA, Madrid, Spain; ^eDivision of Hematology, Mayo Clinic, Rochester, Minnesota, USA; ^fDepartment of Qualitative Health Sciences, Mayo Clinic, Rochester, Minnesota, USA; ^gDepartment of Molecular Medicine, University of Pavia, Pavia, Italy; ^hAmyloidosis Research and Treatment Center, Fondazione IRCCS Policlinico San Matteo, Pavia, Italy; ⁱDepartment of Medicine, Department of Cardiovascular Diseases, Mayo Clinic, Rochester, Minnesota, USA; ^jUniversidad Francisco de Vitoria, Pozuelo de Alarcón, Spain; and the ^kCentro Nacional de Investigaciones Cardiovasculares, Madrid, Spain.

Prem Soman, MD, PhD, served as Guest Associate Editor for this paper. Christopher M. O'Connor, MD, served as Guest Editor-in-Chief for this paper.

The authors attest they are in compliance with human studies committees and animal welfare regulations of the authors' institutions and Food and Drug Administration guidelines, including patient consent where appropriate. For more information, visit the [Author Center](#).

Manuscript received November 16, 2023; revised manuscript received December 29, 2023, accepted January 3, 2024.

ABBREVIATIONS AND ACRONYMS

AL	= light chain amyloidosis
ATTR	= transthyretin amyloidosis
CA	= cardiac amyloidosis
CR	= Congo red
EMB	= endomyocardial biopsy
FFPE	= formalin-fixed paraffin-embedded
IEM	= immunoelectron microscopy
IHC	= immunohistochemistry
LC-MS/MS	= liquid chromatography coupled to tandem mass spectrometry

transthyretin amyloidosis (ATTR) are responsible for most cases of CA in clinical practice, the correct identification of amyloid type is essential given the significant differences in prognosis and treatment among the different types of CA.^{2,7} Moreover, appropriate amyloid typing is also important to adequately recognize hereditary CA forms to provide genetic counseling and facilitate identification of additional affected or at risk family members.⁸⁻¹⁰

Accurate typing of CA has gained relevance as highly effective specific therapies have become available for AL and ATTR.¹¹⁻¹⁴ Nonetheless, initiation of specific therapies requires identification of patients who are

affected by CA, followed by appropriate characterization of the underlying amyloid type. Accurate typing allows initiation of the correct specific therapies, avoiding incorrect initiation of chemotherapy in the presence of a plasma cell dyscrasia unrelated to underlying CA¹⁵ or applying expensive ATTR modifying therapies when they are not indicated.¹⁶

The cornerstone of amyloid histological confirmation is the typing of the amyloid deposits once amyloid fibrils have been identified. Currently, amyloid typing can be achieved by different techniques. Traditionally, typing was performed using antibody-based methods such as immunohistochemistry (IHC) or immunofluorescence, but recently, other more sophisticated techniques like immunoelectron microscopy (IEM) and mass spectrometry have emerged as validated and more specific.^{3,17,18}

In this review, we describe in detail when and how to type amyloid deposits and outline the characteristics and limitations of the different typing techniques to provide guidance on how to correctly interpret and integrate the histopathology results for correct diagnosis and typing of CA.

WHICH PATIENTS REQUIRE AMYLOID HISTOLOGICAL CONFIRMATION?

Although age at presentation, presence of genetic variants, existence of a plasma cell dyscrasia, or typical red flags such as periorbital purpura or ruptured biceps tendon (Popeye's sign) can point toward a specific type, amyloid type must be always confirmed and not assumed.

Although noninvasive ATTR-CA typing is accepted in patients who exhibit a grade 2 or 3 tracer uptake (cardiac uptake similar or greater than bones) with bisphosphonate scintigraphy in combination with negative monoclonal protein screening (negative

HIGHLIGHTS

- A substantial proportion of patients with CA require tissue sampling for diagnosis, and histological typing can inform the prognosis and help guide treatment.
- Histological typing can be achieved by antibody-based or mass spectrometry methods, each of which has advantages and limitations.
- Protocols to improve the performance and expand the availability of tissue typing could improve the evaluation and management of patients with suspected amyloid heart disease.

immunofixation electrophoresis of both serum and urine and normal circulating free light chain measurement), histological demonstration of amyloid deposits and amyloid typing is still required for all patients with AL-CA and those affected by rarer forms of CA such as fibrinogen amyloidosis, lysozyme amyloidosis, apolipoprotein A-IV amyloidosis, apolipoprotein A-I amyloidosis, or gelsolin amyloidosis.^{2,7} Moreover, approximately 20% of patients with grade 2 to 3 cardiac uptake on scintigraphy exhibit abnormalities of monoclonal protein tests, necessitating cardiac histological typing to differentiate between ATTR-CA with monoclonal gammopathy of unknown significance, AL-CA with positive scintigraphy uptake, or the coexistence of both AL and ATTR CA.^{19,20} Last, in patients who show grade 1 tracer uptake on scintigraphy (cardiac uptake less than that of bones) irrespective of monoclonal screening results or those without tracer uptake and monoclonal protein abnormalities but high suspicion of CA, noninvasive diagnosis is not possible and histological confirmation of amyloid deposits is required.^{2,7} **Figure 1** summarizes clinical scenarios in which histological confirmation is required for CA diagnosis.

HISTOLOGICAL CONFIRMATION OF CA

CA is confirmed when amyloid deposits are identified in an endomyocardial biopsy (EMB). Diagnosis of CA can also be confirmed if amyloid deposits are found in an extracardiac biopsy and typical diagnostic features of cardiac involvement either by cardiac magnetic resonance or echocardiography are present.^{2,7} Although the type of CA is frequently assumed to correspond to the type of amyloid identified in extracardiac biopsies, in our clinical experience, this should not be done in older patients who exhibit

TABLE 1 Types of Cardiac Amyloidosis

Amyloidosis Type	Protein Precursor	Cardiac Involvement
AL	Immunoglobulin light chain	70%
ATTRwt	Transthyretin	100%
ATTRv	Transthyretin	30%-100%, depending on genotype
AA	Serum amyloid A	5%
AFib	Fibrinogen- α	Infrequent
AApoA-I	Apolipoprotein A-I	Infrequent, depending on genotype
AApoA-II	Apolipoprotein A-II	Infrequent, depending on genotype
AApoA-IV	Apolipoprotein A-IV	Unknown
A β 2M	β 2-microglobulin	Rare
AGel	Gelsolin	Rare. 5% as conduction disorders
ALys	Lysozyme	Rare

AA = serum amyloid A amyloidosis; AApoA-I = apolipoprotein A-I amyloidosis; AApoA-II = apolipoprotein A-II amyloidosis; AApoA-IV = apolipoprotein A-IV amyloidosis; A β 2M = β 2-microglobulin amyloidosis; AFib = fibrinogen amyloidosis; AGel = gelsolin amyloidosis; AL = immunoglobulin light chain amyloidosis; ALys = lysozyme amyloidosis; ATTRv = hereditary transthyretin amyloidosis; ATTRwt = wild type transthyretin amyloidosis.

cardiac uptake in scintigraphy and who have AL deposits identified in an extracardiac biopsy. These patients should undergo EMB to confirm the nature of the CA deposits, as a combination of ATTR-CA with extracardiac AL amyloidosis can be found in a number of those individuals given the increased prevalence of ATTR-CA with age.^{21,22}

EMB AND SAMPLE PREPARATION. Considering the progressive infiltrative nature of amyloidosis and

given the possible focal distribution of deposits, especially at early stages of the disease, it is crucial to obtain a sufficient number of EMB biopsy fragments to avoid false-negative results. It is recommended to obtain at least 3 cardiac samples to undergo multiple sections, but there is no evidence whether right or left ventricle biopsy provides better results and it may depend on each center’s experience.

In contrast to general pathology, in which 3- to 5- μ m sections are usually employed, although there is no consensus, we recommend to use 10- μ m sections for Congo red (CR) and thinner sections of 4 μ m for hematoxylin and eosin staining because deposits could be missed or false-positive results could be obtained with thinner sections.

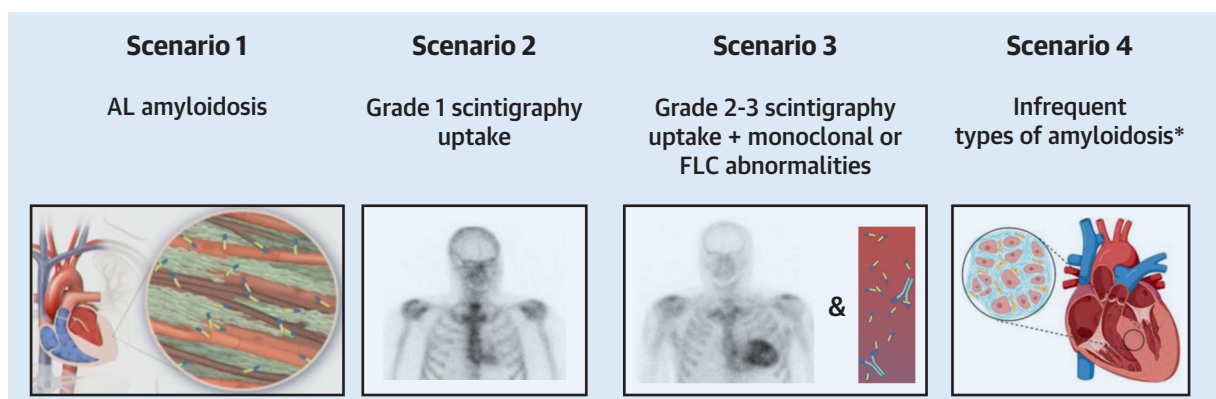
SUSPICION AND HISTOLOGICAL CONFIRMATION.

The first step in the diagnostic process of the histological confirmation of CA is to convey the clinicians’ suspicion to the pathologist.

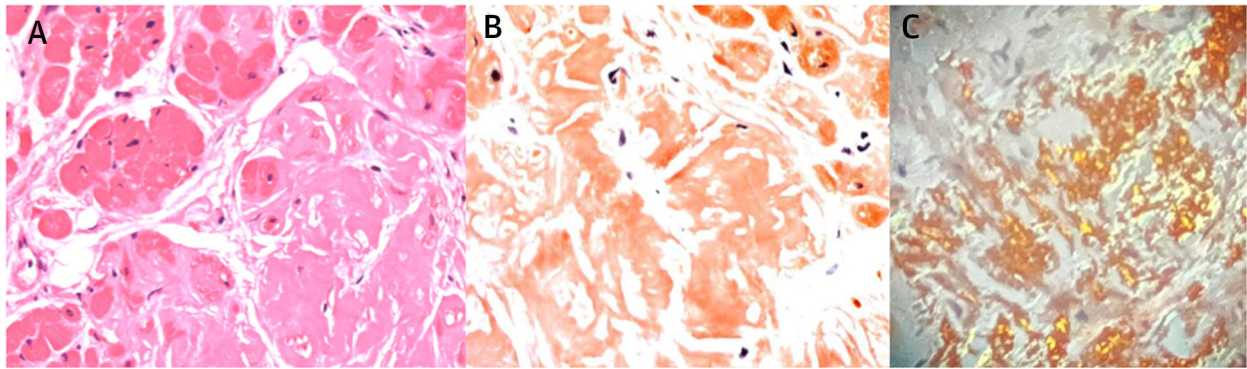
Amyloid can be identified or suspected on hematoxylin and eosin samples. Although not specific, because hyaline changes or sclerosis can be similar in appearance,²³ amyloid appears as a light pink amorphous and homogeneous extracellular substance with hematoxylin and eosin²⁴ (Figure 2A) regardless of the location of amyloid deposits in different organs. Of note, a digitally reinforced hematoxylin and eosin polarization technique has been proposed to improve amyloid detection, especially when tissue is scarce.²³

Once amyloid is identified or suspected, it should be confirmed using a special stain. CR, introduced by Bennhold in 1922,²⁵ is the most common one. Using a

FIGURE 1 Clinical Scenarios Where Cardiac Amyloid Histological Typing Is Required



This figure illustrates the different possible clinical scenarios in which histological confirmation is required for cardiac amyloid diagnosis. *Infrequent types of amyloidosis include patients with certain TTR genetic variants and Grade 0 scintigraphy uptake. AL = light chain amyloidosis; FLC = free light chain.

FIGURE 2 Histological Identification and Confirmation of Amyloid Deposition on Endomyocardial Biopsy

(A) Amyloid appears as a light pink, amorphous, homogeneous extracellular substance with hematoxylin and eosin ($\times 200$). (B) Congo red staining ($\times 200$). (C) Amyloid deposition confirmed by green birefringence under cross-polarized light with Congo red staining.

CR stain, amyloid deposits will appear red or salmon-pink on light microscopy.²³ Under cross-polarized light, deposits demonstrate green birefringence, considered pathognomonic and diagnostic of amyloid deposition (**Figure 2B**). All forms of amyloid have affinity for CR, and although CR may stain other structures, this typical green birefringence distinguishes amyloid from other fibrils and from the white birefringence of fibrin or collagen.^{23,26}

If possible, CR staining should be performed routinely in all native endomyocardial biopsies even in clinically unsuspected cases, because the differential diagnosis is limited and small amyloid deposits could be inconspicuous by hematoxylin and eosin.

When CR is negative and there is a high clinical or morphologic suspicion of CA, staining should be repeated in other sections, because the type of tissue, the type of amyloid fibrils, and the protocols used could affect the results. In these cases, we recommend thicker slices and to prolong deparaffination time. Moreover, interobserver variability and technician and pathologist's experience play an important role. Also, CR is a technically difficult stain: the procedure must include positive controls, and it should be followed exactly to achieve good and reproducible results. We recommend modified Puchtler's method.²⁷ This method applies alizarin red S at pH 9, allowing both the sulphonate group on carbon 3 and the ionized hydroxy group on carbon 2 to participate in salt formation with calcium. Puchtler's modified method, with less sodium chloride and alcohol, provides more stable staining, saves time, and leads to

consistent and reliable results.²⁷ To increase the sensitivity and specificity of CR, evaluation of CR-stained sections by fluorescent light caused by the fluorescent properties of this staining has been proposed.²⁸

Conversely, positive CR staining with no histologic evidence of extracellular deposition should be re-evaluated. If that is the case, comparing morphological findings and birefringence tissue sites or using alternate stains is desirable.

Alternate stains that could be used for amyloid diagnosis include Thioflavin T, Thioflavin S, or Alcian blue, which binds to glycosaminoglycans in fibrils. Although Thioflavin T is less specific than CR, Thioflavin T binds to β -sheets rich structures and appears yellow, shifting to red under fluorescence enhancement.²⁹ In our experience, Thioflavin T is very sensitive and can be performed both in paraffin-embedded and frozen tissue, although the latter is often not available. Azan Mallory trichrome is also another option that could be useful in the differential diagnosis with collagen, showing amyloid as bluish-gray.¹⁷ Amyloid does not stain with methenamine silver stains and appears blue or gray on trichrome stain.²³

AMYLOID DEPOSITS IN THE HEART. Amyloid deposits infiltrate both the myocardium and the cardiac vessels, but its distribution is variable in location and extent. At early stages, initial amyloid deposits in the interstitium or intramyocardial vessels' walls may be focal and therefore difficult to detect.

Once deposits are larger, the infiltrative pattern could be different between the myocardium and the

TABLE 2 Characteristics of Cardiac Amyloid Histological Typing Techniques

	Requirements	Yield	Strengths	Limitations	Availability and Costs
IHC	<ul style="list-style-type: none"> • FFPE cardiac samples • Antibody-based method 	<ul style="list-style-type: none"> • Dependent on sensitivity and specificity of antibodies • Unable to classify samples depending on center's expertise and era (6%-80% inconclusive findings reported) 	<ul style="list-style-type: none"> • Availability • Affordable • Short time to results 	<ul style="list-style-type: none"> • Low specificity for AL • Possible lack of staining and multiple reactions with various antibodies • Background staining and false-positive cases • Lack of availability of antibodies for all CA subtypes • Potential for assigning an incorrect amyloid type • Requires training and expertise from technicians and pathologists 	<ul style="list-style-type: none"> • Widely available • Small cost
IEM	<ul style="list-style-type: none"> • Antibody-based method • Modified Karnovsky's solution for sample fixation • FFPE samples also possible • Electron microscopy 	<ul style="list-style-type: none"> • 80% sensitivity and 100% specificity in abdominal fat aspirate • Close to 100% sensitivity and specificity in EMB 	<ul style="list-style-type: none"> • Detection of small deposits • Minimizes background staining • High specificity using commercial antibodies 	<ul style="list-style-type: none"> • Tiny deposits could be missed • Dependent on good tissue fixation • Lack of availability of antibodies for all CA subtypes • Requires training and expertise from technicians and pathologists 	<ul style="list-style-type: none"> • Very limited availability • Intermediate cost (high-cost infrastructure)
LC-MS/MS	<ul style="list-style-type: none"> • FFPE cardiac samples • Laser microdissection • Liquid chromatography • Tandem mass spectrometry • Bioinformatics 	<ul style="list-style-type: none"> • Gold-standard for amyloid typing • Very high sensitivity and specificity 	<ul style="list-style-type: none"> • Objective and unambiguous • Tiny amounts of tissue required • All amyloid types can be identified • Able to distinguish between wild-type and hereditary forms 	<ul style="list-style-type: none"> • Multiple-step and complex process • Longer time to results • Requires training and expertise from technicians and pathologists 	<ul style="list-style-type: none"> • Limited availability • High cost

AL = light chain amyloidosis; CA = cardiac amyloidosis; EMB = endomyocardial biopsy; FFPE = formalin-fixed and paraffin-embedded; IEM = immunoelectron microscopy; IHC = immunohistochemistry; LC-MS/MS = liquid chromatography and mass spectrometry.

vessels. At a myocardial level, 2 interstitial patterns can be distinguished and coexist: amyloid can be found surrounding cardiomyocytes individually, following a pericellular pattern, leading to atrophy and progressive loss of cardiomyocytes; or presenting as nodular amyloid aggregates that alter the normal structure of the myocardium and replace it.³⁰

Although the pattern of amyloid deposition does not differentiate between CA types, some differences can be recognized between AL and ATTR deposits. AL-CA deposits are mainly pericellular and reticular and accompanied by inflammatory infiltrates.³¹ On the contrary, ATTR deposits are mainly irregular and patchy, following a nodular pattern along with diffuse interstitial deposition or thin interstitial and vascular deposits.³² However, there is considerable overlap, and morphologic distribution is not a reliable indicator of amyloid type.

In the vessels, amyloid can affect both arteries and veins, epicardial or intramyocardial, and capillaries. Vessels' amyloid infiltration could be perivascular, affecting partially or entirely the vessels' circumference or affecting just the medial layer, the intima, or the entire wall and causing obstruction of the vessels.²⁵

Finally, secondary histological changes may accompany amyloid deposition such as presence of

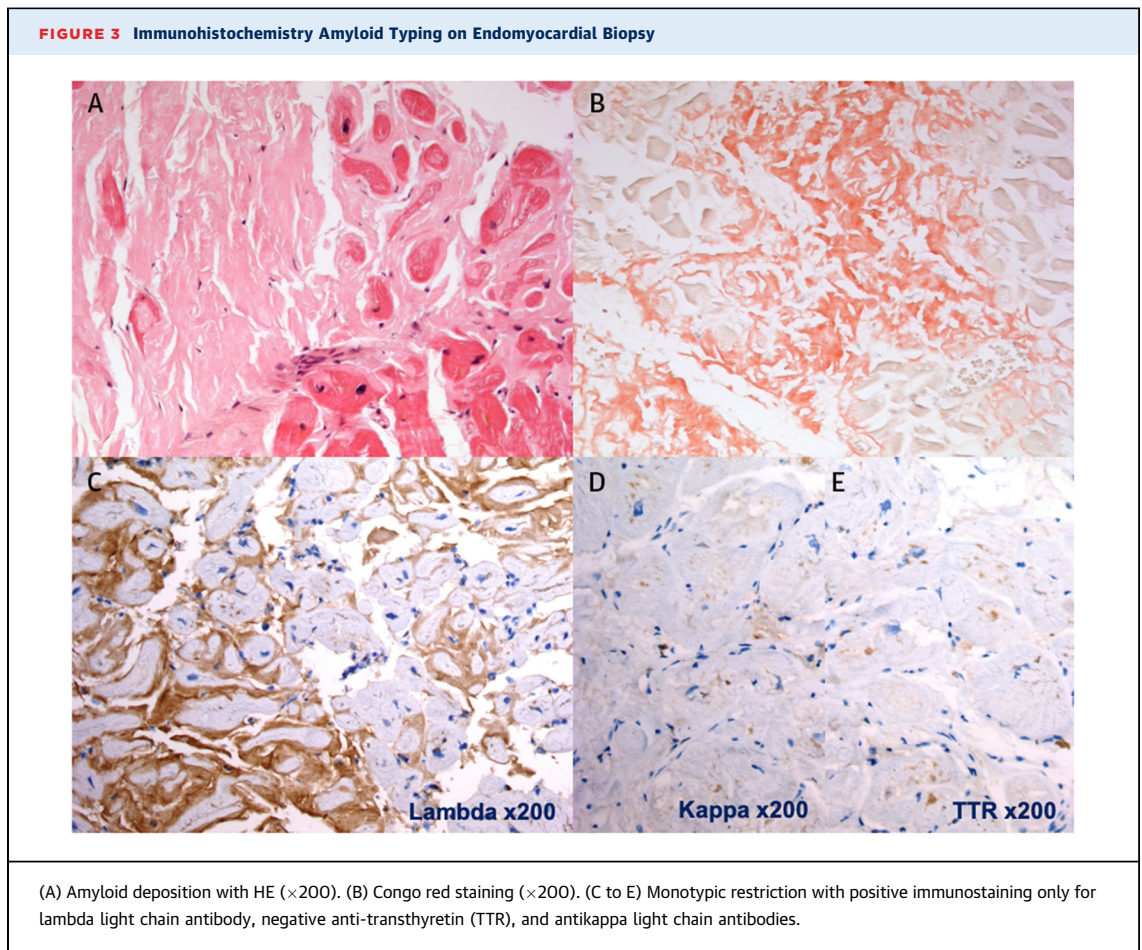
inflammatory cells, attenuation or atrophy, vacuolization or reactive hypertrophy of cardiomyocytes, or even ischemic-like damage.²⁵

AMYLOID TYPING TECHNIQUES

Once amyloid deposits are confirmed, identification of the type of amyloid fibril protein should follow. Antibody-based methods or mass spectrometry are the currently available typing techniques with different strengths and limitations (Table 2). It is important to underline that these methods are complementary, and it is important to understand their yield to interpret the results.

1. IMMUNOHISTOCHEMISTRY. Method description and requirements. IHC is based on the use of antibodies against normal or aberrant protein epitopes within amyloid fibrils (Figure 3).

Yield/performance of IHC. IHC has a variable yield depending on the protocol used, the quality of the antibodies, as well as the experience of the laboratory and the pathologist. The way samples are prepared is critical. How tissue is processed based on the type of formalin, the duration, and the temperature of fixation can make a great difference.³³ Overfixation may interfere with tissue antigenicity and lead to false



positives caused by high background. Insufficient fixation can also be problematic. To avoid overfixation, we recommend processing samples on the same day, just a few hours after formalin fixation.

Second, quantity and quality of antibodies is crucial on Formalin-fixed paraffin-embedded (FFPE) samples. Sensitivity and specificity of commercial antibodies vary, with very high sensitivity and specificity in some cases.¹⁷ Nevertheless, sensitivity and specificity of commercial antibodies might vary even when acquired from the same supplier, and every time a new set of antibodies is acquired, we recommend undertaking antibody testing with a set of CA and control samples with several dilutions of the antibody to determine the most appropriate conditions. Laboratories at referral amyloid centers may have their own validated panel of noncommercial monoclonal antibodies. Last, it is critical to always use a combined panel of antibodies including at least antibodies for TTR, AA, and lambda and kappa chains, because interpretation of IHC results using an

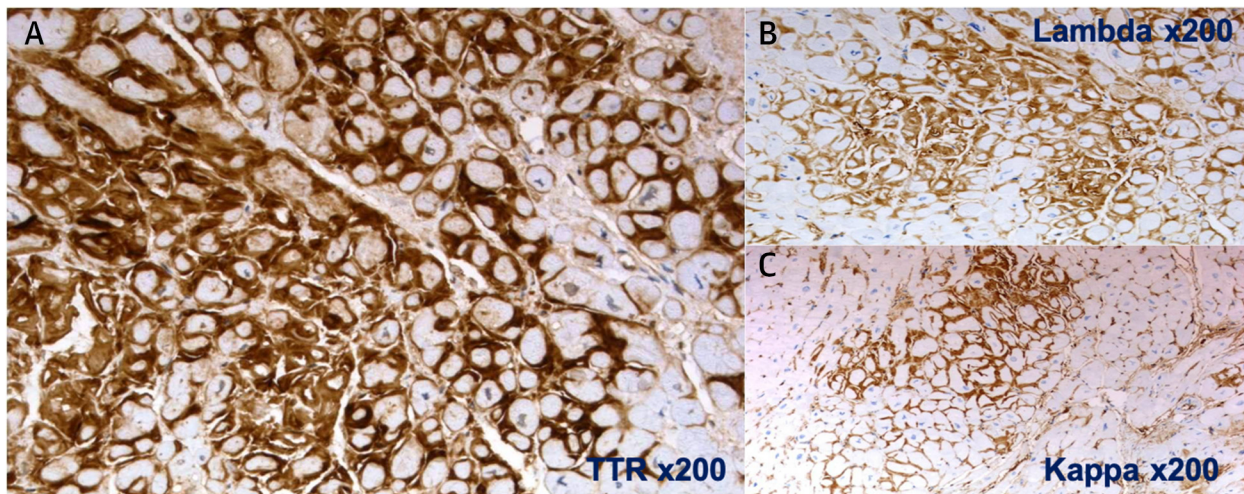
incomplete panel of antibodies can lead to incorrect typing.

Performance of IHC in typing CA varies in the literature depending on the series and centers.³³ In a German cohort of 117 patients, IHC was described to have a sensitivity of 96% with a yield of 92% for typing.³³ Nevertheless, despite optimal preparation, a proportion of samples with CA remain unclassified even at experienced centers. In the literature, cases of unclassified CA range from 6% in recent studies to 80% in older series.^{33,34}

Strengths and limitations. The main strength of IHC is its wide availability and lack of need for specific equipment, which makes the technique affordable for any specialized pathology department.

However, there are 2 main limitations to using antibody-based methods to type amyloid. First, amyloid typing by IHC can lack both sensitivity and specificity. Antibodies used in IHC are produced against native proteins, which have a regular length

FIGURE 4 Inconclusive Immunohistochemistry on EMB



Intense antitransferrin (TTR) reactivity (A) concomitant with mild antilambda (B) and antikappa (C) light chain staining, requiring further methods for amyloid typing. TTR amyloidosis was confirmed by mass spectrometry.

and conformation while amyloid fibrils may be truncated by mutations or fragmented, they could also show conformational and post-translational alterations, which can lead to altered or loss of epitopes, resulting in poor or no antibody reactivity.²³

This is particularly problematic with commercial antibodies against light chains. Antibodies targeting kappa or lambda light chains are produced against the constant region and usually react with the intact immunoglobulin.²³

This could make AL amyloid fibrils difficult to detect because there may be conformational differences between native and tissue-fixed light chains given the heterogeneity because of their prominent variable domain and fragmentation during amyloid fibril formation.³⁵ This can lead to false-negative results. There is also a risk of false-positive results caused by cross-reactivity with deposited immunoglobulins, resulting in low specificity of IHC for AL-CA.³⁶ In contrast, anti-AA and -TTR antibodies have a stronger and more reliable staining,³³ despite this, inconclusive results with these antibodies can also be obtained.

In ATTR, intense TTR IHC consistent with CR-positive deposits and without monotypic restriction for immunoglobulin light chains should be found. Unfortunately, lack of staining and multiple reactions of a single amyloid deposit with various antibodies can occur, especially with anti-TTR, antilambda and

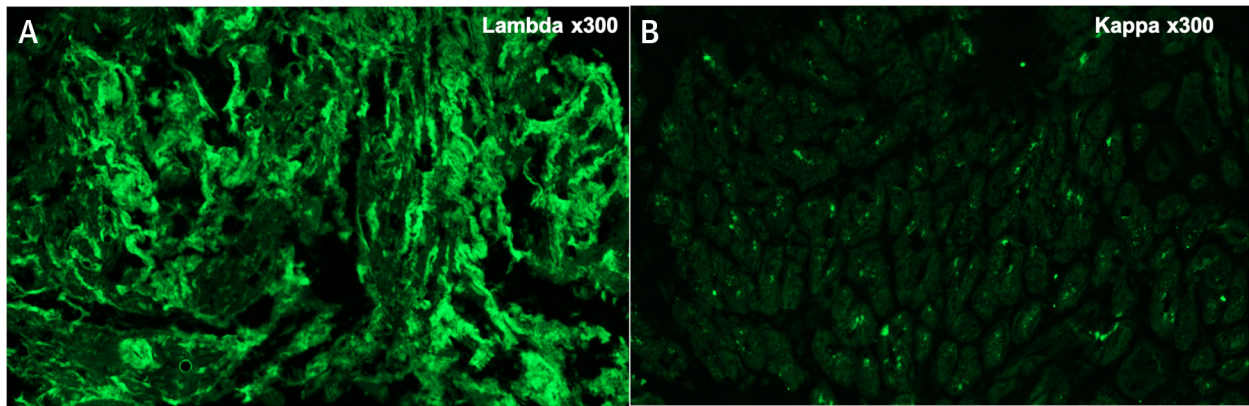
antikappa (Figure 4). These challenging cases are not rare even at experienced centers and require additional techniques to confirm the CA subtype.¹⁷ Direct immunofluorescence is used at the Hospital Universitario Puerta de Hierro in Madrid. This technique is mostly used for kidney samples because it usually requires fresh/frozen tissue. In our experience, adapting the settings for FFPE cardiac samples can also provide good results and limit the number of samples with inconclusive staining (Figure 5).³⁷

Another limitation of IHC is the availability of antibodies for all CA subtypes. Anti-TTR, anti-AA, antilambda, and antikappa are easily found, but antibodies against other protein precursors might be unavailable or difficult to find, thus not allowing detection of more unusual amyloid types. This can potentially result in assigning an incorrect amyloid type.

Additionally, background staining is not uncommon and may lead to false-positive cases. This is indeed the most common cause of reduced specificity in IHC. It could be caused by nonimmunological binding or the presence of normal proteins containing epitopes targeted by the antibody in the extracellular space.^{38,39}

Last, performance and interpretation of the technique relies on technicians and pathologist's training and experience. In equivocal cases, referring samples to a specialized center is advised.

FIGURE 5 Light and Immunofluorescence Microscopy in Light Chain Amyloidosis With Masked Deposits



(A) Positive lambda chains staining in the interstices in paraffin-embedded tissue after pronase digestion (direct immunofluorescence) ($\times 300$). (B) Negative staining for kappa light chains by paraffin immunofluorescence (direct immunofluorescence) ($\times 300$).

Costs and availability. Although costs might vary across countries and health systems, IHC is the most accessible typing method. Usual turnaround time of results is between 2 and 7 days. As previously stated, IHC is the most widely available method for amyloid typing and is usually the starting typing method used at many centers, because it is a reliable technique in experienced hands.

2. IMMUNOELECTRON MICROSCOPY. Method description and requirements. The interpretation of the CR stain birefringence pattern under polarized light could be challenging.³⁵ In contrast, by electron microscopy (EM), whatever the amyloidogenic protein may be, amyloid deposits typically appear as randomly oriented, nonbranching fibrils measuring 8 to 10 nm in diameter, quite different from collagen fibers, which are much thicker and show a characteristic banding pattern (Figure 6).

The ultrastructural examination of biopsy samples by EM can confirm or exclude the diagnosis of amyloidosis and can identify even very small deposits of amyloid fibrils.⁴⁰

IEM is a technique that combines IHC and EM.⁴¹ Using gold-labeled secondary antibodies, IEM allows the correlation of immunostaining and amyloid fibrils morphology and minimizes background staining, overcoming the need for custom-made antibodies.³³

In the processing of biopsy samples for EM, good fixation plays a very important role. Although glutaraldehyde, the fixative commonly used in EM

laboratories, is excellent in preserving morphology, it severely inactivates the immunoreactivity of many antigens; hence, a better fixative for IEM is a mixture of paraformaldehyde and glutaraldehyde (modified Karnovsky's solution).⁴⁰

After fixation, specimens are postfixed in osmium tetroxide, dehydrated through a graded series of ethyl alcohols, and embedded in epoxy resin. Ultrathin sections are cut with an ultramicrotome at 700 to 800 Ångström and stained with uranyl acetate and lead citrate.

FFPE samples can also be processed for ultrastructural examination and IEM, allowing the use of stored material for the characterization of amyloid proteins. In this case, selected portions of tissue are extracted from the paraffin block with a scalpel, deparaffinized in xylene, rehydrated in a graded series of ethyl alcohols, postfixed in osmium tetroxide, and embedded in epoxy resin as in the previous text.

Selected ultrathin sections are then processed for postembedding immunogold as follows: after enzymatic predigestion with trypsin, sections are incubated with either normal goat serum or egg albumin and subsequently with the primary antibodies. Commercial antibodies are frequently used as primary antibodies.

The ultrathin sections are then incubated either with a secondary antibody (antirabbit or antimouse immunoglobulin G) or with protein-A, both of which are conjugated to 10- to 20-nm-sized colloidal gold

particles that decorate amyloid fibrils and allow the recognition of the amyloidogenic protein.

Characteristics of IEM. The sensitivity of IEM in abdominal fat aspirates of patients with systemic amyloidosis is good (80%), with 100% specificity and positive predictive value,⁴¹ and IEM on fat tissue for CA shows high sensitivity and specificity.⁴⁰

In patients with ATTRwt amyloidosis, the abdominal fat aspiration has shown only 43% sensitivity, so EMB is often necessary;⁴² in this case, IEM has been reported to have a 100% sensitivity and specificity.⁴⁰

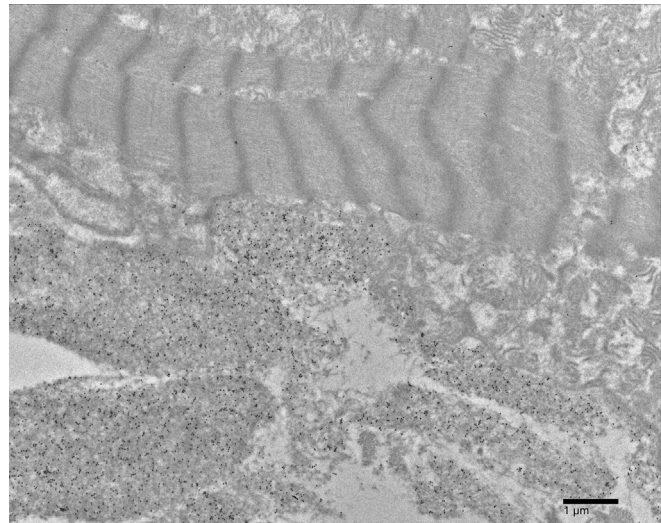
Strengths and limitations of IEM. The focality of amyloid deposits contributes to the limitations of the IEM technique, because specimens are small in size and scarce deposits may, therefore, be missed. On the other hand, very small deposits of amyloid fibrils reacting with antibodies can be identified by IEM, increasing the sensitivity of the examination. IEM can be applied to virtually every tissue, either specifically fixed for ultrastructural examination or previously FFPE.

Limitations of IEM include dependence on good tissue fixation and on the availability of good antibodies to the amyloidogenic protein. It must be emphasized, however, that unlike IHC, commercial antibodies show a very high specificity in IEM. Besides, IEM requires access to EM facilities and skilled technicians and pathologists specifically trained for processing of specimens and interpretation of the results. IEM also lacks sensitivity for unusual amyloid types because it also depends on the availability of antibodies against those proteins.

Costs and availability. IEM is available for the diagnosis and typing of amyloidosis only in a few centers worldwide. In the United States, it is only available currently at Boston University. The instruments are relatively expensive, and the reagents may be expensive too, although the limited amount of antibodies needed (a few microliters) contributes to cost containment.

3. MASS SPECTROMETRY-BASED PROTEOMICS. To overcome limitations of IHC and IEM, a technique to identify the proteins in an amyloid deposit directly using liquid chromatography (LC) coupled to tandem mass spectrometry (MS/MS) was developed.^{36,43} Mass spectrometry proteomics allows identification of the proteins that comprise the amyloid deposits in an unbiased and untargeted fashion. This assay is

FIGURE 6 Endomyocardial Biopsy Sample in Immunoelectron Microscopy




(Top part of image) A myocardial fibril cell with myofibrils. (Bottom part of image) Bundles of amyloid fibrils immunostained with anti-TTR polyclonal antibody (DAKO Agilent). Revealing system: goat antirabbit immunoglobulin G conjugated with 10-nm gold particles (BBI Solutions).

considered the gold standard method for amyloid typing.

Method description and requirements. Amyloid typing by LC-MS/MS was originally developed for analysis of FFPE tissue specimens³⁴ and was subsequently adapted for typing wet fat aspirate specimens.^{36,44,45} Some amyloid reference centers, including the Mayo Clinic in Rochester, use laser microdissection to excise CR-positive protein deposits before analysis, thereby enriching the specimen for amyloid proteins and minimizing the contribution from uninvolved tissue.⁴⁶ Although we highly recommend using laser microdissection before LC-MS/MS, other centers describe good results without it.

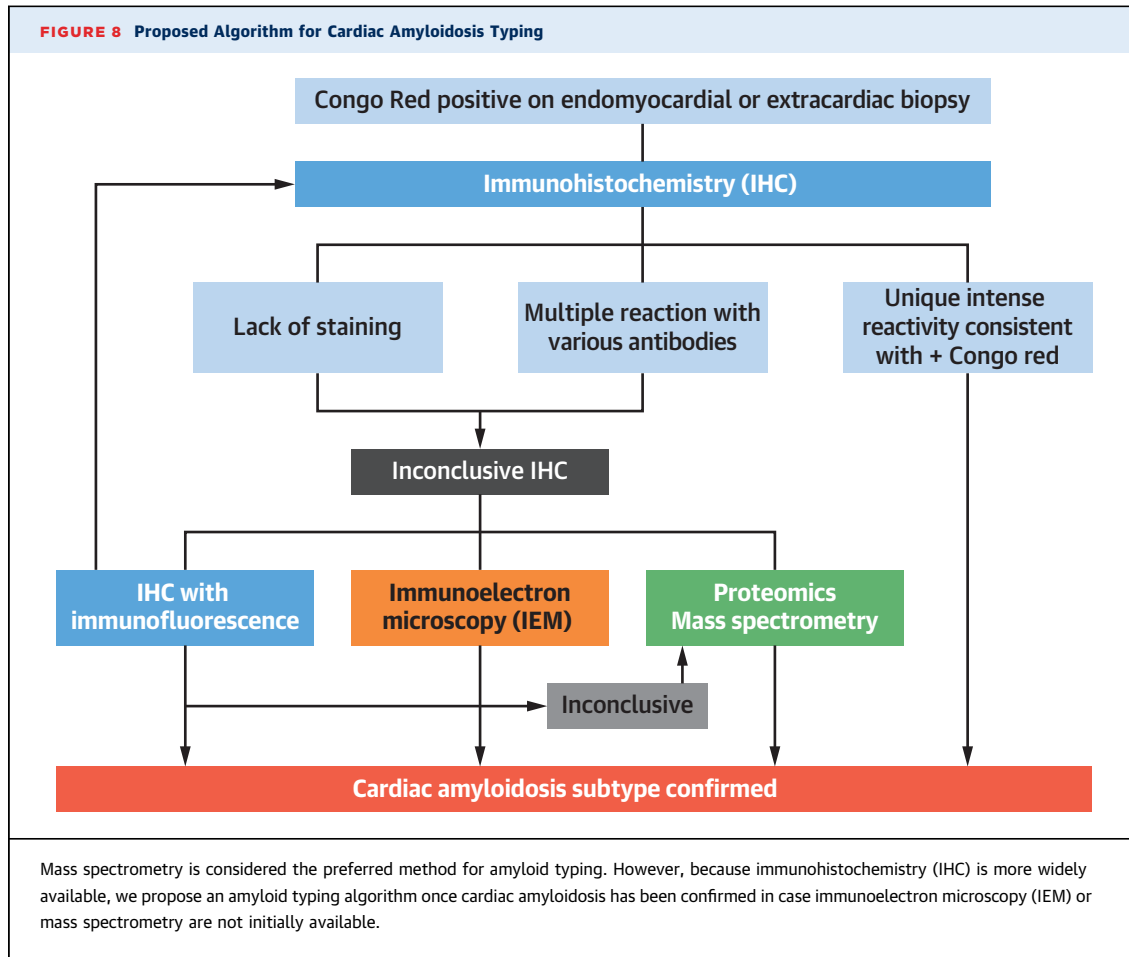
At the Mayo Clinic, the following technique is used: 10- μ m-thick sections of FFPE tissues are stained with CR, and CR-positive deposits identified under fluorescent light are excised using laser microdissection. Two independent microdissections are performed for each case. Material measuring 60,000 μ M² in area is captured for each dissection, and FFPE fragments from each microdissection are analyzed individually. Proteins then undergo heat extraction, sonication denaturation, and trypsin

FIGURE 7 Mass Spectrometry in an Endomyocardial Biopsy Incorrectly Diagnosed as Light Chain Amyloidosis by Immunofluorescence

(A) Congo red-stained section viewed under UV light source. The interstitial/nodular Congophilic deposits show bright red fluorescence, confirming amyloid deposition. The area selected for microdissection is circled with a purple line. (B) The corresponding proteome profile by mass spectrometry demonstrates transthyretin amyloidosis (ATTR)v-type amyloid. The blue stars highlight the amyloidogenic transthyretin (TTR) protein (line 1) and the mutant TTR protein with V122I (p.Val142Ile) variant (line 2), and the yellow stars highlight the universal amyloid proteins (apolipoprotein E, apolipoprotein A-IV, and serum amyloid P component). Numbers in the green boxes indicate total number of tandem mass spectrometry spectra matching a protein in a sample, which is a surrogate measure of its abundance.

digestion. The resulting peptide mixture is analyzed on a QExactive-Plus mass spectrometer (Thermo-Fisher) connected to a Dionex (Thermo-Fisher) nano-flow LC system. Three different database search engines (Comet, X!Tandem, and Mascot) are

used to match the MS/MS spectra present in each raw file against the SwissProt human proteome augmented with common contaminants. Reverse protein sequences are used as decoys for estimating peptide and protein identification probabilities.



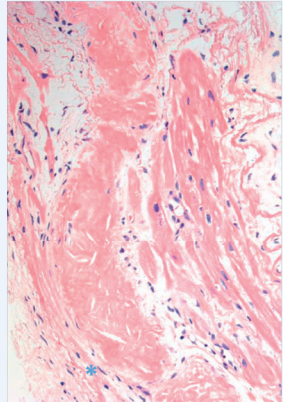
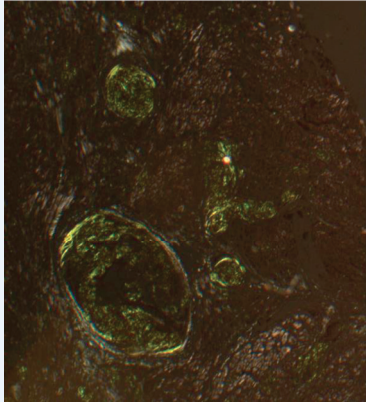
Scaffold software processes all peptide matches and assembles protein identifications while treating raw files from replicate dissections as biological replicates. Proteins with at least single confident unique peptide identification (probability >0.9) and more than 5 spectral matches are considered for clinical interpretation.^{47,48}

Based on this analysis, a personalized proteomic profile is created for each patient that lists all of the confident protein identifications present in each dissection and their respective MS/MS spectral counts. A pathologist then reviews the proteomic profile. The proteomic profile is assessed for the presence of the amyloid signature proteins (apolipoprotein E, serum amyloid P component, and apolipoprotein AIV), which are proteins that may be found in all types of amyloid deposits and are further proof that the CR-positive material is indeed amyloid. If an amyloid signature is present, then the amyloid type is identified based on the most

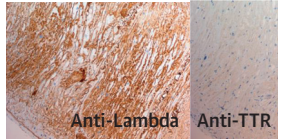
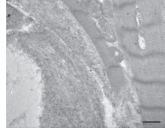
abundant amyloidogenic protein that was consistently detected across the replicate analyses, in conjunction with review of the clinical information, hematoxylin and eosin morphology, CR staining, and laser microdissection images. See example in **Figure 7**.

LC-MS/MS can also detect amino acid substitutions in cases of hereditary amyloidosis using a modified bioinformatics pipeline. At Mayo Clinic, a custom protein sequence database augmented with all known amyloidogenic amino acid substitutions using the MS/MS spectra generated from the routine amyloid typing data is used to detect specific amino acid substitutions that distinguish mutated proteins from wild-type proteins. Previous validation studies of this method against the gold standard of Sanger sequencing of the genes for the corresponding mutated amyloid proteins demonstrated high sensitivity (92%) and specificity (100%).⁴⁹ However, the current clinical standard

CENTRAL ILLUSTRATION Cardiac Amyloidosis Typing Methods

Suspicion	Diagnosis
 <p>Light pink amorphous extracellular material on hematoxylin-eosin</p>	 <p>Green birefringence with Congo red staining under polarized light microscopy</p>

Typing

Immunohistochemistry	Immunoelectron Microscopy
 <p>Anti-Lambda Anti-TTR</p> <p>Antibody-based method. Low specificity in AL forms but generally available.</p>	 <p>Antibody-based method. High sensitivity and specificity, variable depending on tissue.</p>

Mass Spectrometry

#	Starred	Bio View: Identified Proteins (66/78) Including 0 Decoys	Molecular Weight	Probability Legend:	
				Sample 1	Sample 2
1	★	Ig lambda-2 chain C regions	11 kDa	161	163
2	★	Ig lambda chain V-VI region SUT	12 kDa	102	76
3	★	Apolipoprotein E	36 kDa	160	120
4	★	Apolipoprotein A-IV	45 kDa	47	45
5	★	Serum amyloid P-component	25 kDa	18	18

Preferred method but limited access.

Prognostic and Therapeutic Implications

Gonzalez-Lopez E, et al. J Am Coll Cardiol. 2024;83(11):1085-1099.

Amyloid histological typing has significant prognostic and treatment implications. Amyloid typing can be performed by mass spectrometry, immunohistochemistry, and immunoelectron microscopy, with each technique having its pros and cons. AL = light chain amyloidosis; TTR = transthyretin.

still mandates gene sequencing to confirm hereditary amyloidoses.

Strengths and limitations of LC-MS/MS. Amyloid typing by LC-MS/MS has multiple advantages. Unlike antibody-based methods, this shotgun proteomic method directly analyzes the proteins within the amyloid deposit and thus can identify all amyloid types in a single assay. The assay is unbiased, efficient, and unambiguous; has very high sensitivity and specificity; and requires only a very small amount of tissue. Paraffin blocks are durable and ubiquitous, and amyloid typing by LC-MS/MS can be performed successfully on decades-old paraffin blocks. Furthermore, the untargeted nature of the assay can foster the identification of novel amyloid types. If a CR-positive deposit contains the amyloid signature proteins but lacks a known precursor protein, the amyloid proteome can be further assessed for the presence of potential novel amyloid fibril proteins. Several canonical amyloid types, including ALECT2 (leukocyte chemotactic factor-2), apolipoprotein A-IV amyloidosis (apolipoprotein AIV), AApoCIII (apolipoprotein C3), AEFEMP1 (EGF-containing fibulin-like extracellular matrix protein 1), ASom (somatostatin), and AIL1RAP (interleukin-1 receptor antagonist protein), have been identified using this method.^{46,50-53}

However, the complexity of the assay is a significant hurdle and may hinder broader clinical implementation. The success of the assay is contingent on a robust quality assurance/quality control program to track metrics pertaining to all aspects of the test, including specimen processing, laser microdissection, sample preparation, liquid chromatography, MS/MS, and bioinformatics. Also, although very little tissue is needed, occasionally there is too little CR-positive material to perform the assay. Occasionally, the amyloid type cannot be determined by LC-MS/MS, but this almost never occurs in endomyocardial amyloid specimens. Potential barriers to broader implementation include lack of standardization of sample processing and instrumentation, challenges in quality management to ensure long-term reproducibility, and adequate training of clinical laboratory personnel. Establishment of a new laboratory requires a significant upfront investment in time, instrumentation, personnel, and bioinformatics.

In addition, amyloid typing by LC-MS/MS is an ancillary tool but should not be used as an independent clinical test. The ultimate tissue diagnosis should be made by a pathologist or hematopathologist with expertise in amyloidosis, by taking into account all clinical and morphologic features

coupled with the result of the LC-MS/MS amyloid typing test.

Costs and availability. Amyloid typing by LC-MS/MS is available as a clinical test in several laboratories around the world. These centers usually accept FFPE samples sent for specialized amyloid typing. Cost varies across countries and centers but often is significantly more expensive than IHC and IEM. Typical turnaround time is 10 to 14 days.

INTEGRATION OF AMYLOID TYPING TECHNIQUES

Due to its robustness and the opportunity to detect all forms of amyloid and even detect new types, we consider LC-MS/MS to be the preferred technique for amyloid typing. In case MS is not routinely available an algorithm for combining amyloid typing, a method starting with IHC, which is the most available technique, is proposed in [Figure 8](#).

CONCLUSIONS

Typing of the amyloid deposits to identify the precursor amyloid protein is a critical step of the diagnostic process of patients affected by CA ([Central Illustration](#)). Either antibody-based techniques, like IHC and IEM, or mass spectrometry can be used to determine the amyloid type. Each method has its advantages and pitfalls, and it is important that physicians diagnosing patients with CA become familiar with these techniques so they can appropriately use them.

FUNDING SUPPORT AND AUTHOR DISCLOSURES

This study has been partially supported by Instituto de Salud Carlos III through the projects “PI18/0765 and PI20/01379” (cofunded by European Regional Development Fund/European Social Fund “A way to make Europe”/“Investing in your future”). The Centro Nacional de Investigaciones Cardiovasculares is supported by the Instituto de Salud Carlos III, the Ministerio de Ciencia e Innovación, the Pro-Centro Nacional de Investigaciones Cardiovasculares Foundation, and the Severo Ochoa grant (CEX2020-001041-S). This work was also supported by grants from the Italian Ministry of Health (Ricerca Finalizzata, grant #GR-2018-12368387), the Italian Ministry of Research and Education (PRIN 20207XLJB2), Cancer Research UK 4013 (C355/A26819), Fundación Científica Asociación Española Contra el Cáncer, and AIRC under the Accelerator Award Program. The authors have reported that they have no relationships relevant to the content of this paper to disclose.

ADDRESS FOR CORRESPONDENCE: Dr Esther Gonzalez-Lopez OR Dr Pablo Garcia-Pavia, Department of Cardiology, Hospital Universitario Puerta de Hierro, Manuel de Falla, 2, 28222 Madrid, Spain. E-mail: esthgonzalez@hotmail.com OR pablogpavia@yahoo.es.

REFERENCES

- Buxbaum JN, Dispenzieri A, Eisenberg DS, et al. Amyloid nomenclature 2022: update, novel proteins, and recommendations by the International Society of Amyloidosis (ISA) Nomenclature Committee. *Amyloid*. 2022;29:213-219.
- García-Pavía P, Rapezzi C, Adler Y, et al. Diagnosis and treatment of cardiac amyloidosis: a position statement of the ESC Working Group on Myocardial and Pericardial Diseases. *Eur Heart J*. 2021;42:1554-1568.
- Dasari S, Theis JD, Vrana JA, et al. Amyloid typing by mass spectrometry in clinical practice: a comprehensive review of 16,175 samples. *Mayo Clin Proc*. 2020;95:1852-1864.
- González-López E, Gallego-Delgado M, Guzzo-Merello G, et al. Wild-type transthyretin amyloidosis as a cause of heart failure with preserved ejection fraction. *Eur Heart J*. 2015;36:2585-2594.
- Castaño A, Narotsky DL, Hamid N, et al. Unveiling transthyretin cardiac amyloidosis and its predictors among elderly patients with severe aortic stenosis undergoing transcatheter aortic valve replacement. *Eur Heart J*. 2017;38:2879-2887.
- Aimo A, Merlo M, Porcari A, et al. Redefining the epidemiology of cardiac amyloidosis. A systematic review and meta-analysis of screening studies. *Eur J Heart Fail*. 2022;24:2342-2351.
- Kittleson MM, Ruberg FL, et al. 2023 ACC expert consensus decision pathway on comprehensive multidisciplinary care for the patient with cardiac amyloidosis: a report of the American College of Cardiology Solution Set Oversight Committee. *J Am Coll Cardiol*. 2023;81:1076-1126.
- Porres-López E, de Frutos F, Silva-Hernández L, et al. Hereditary transthyretin amyloidosis caused by p.Ser43Asn variant. A new endemic variant in Ecuador. *Rev Esp Cardiol*. 2023;76:564-566.
- de Frutos F, Ochoa JP, Gómez-González C, et al. Phenotype and clinical outcomes of Glu89Lys hereditary transthyretin amyloidosis: a new endemic variant in Spain. *Amyloid*. 2023;30:199-207.
- Maestro-Benedicto A, Vela P, de Frutos F, et al. Frequency of hereditary transthyretin amyloidosis among elderly patients with transthyretin cardiomyopathy. *Eur J Heart Fail*. 2022;24:2367-2373.
- Maurer MS, Schwartz JH, Gundapaneni B, et al. Tafamidis treatment for patients with transthyretin amyloid cardiomyopathy. *N Engl J Med*. 2018;379:1007-1016.
- Adams D, Tourneval IL, Taylor MS, et al. Efficacy and safety of vutrisiran for patients with hereditary transthyretin mediated amyloidosis with polyneuropathy: a randomized clinical trial. *Amyloid*. 2023;30:1-9.
- Kastritis E, Palladini G, Minnema MC, et al. Daratumumab-based treatment for immunoglobulin light-chain amyloidosis. *N Engl J Med*. 2021;385:46-58.
- Kastritis E, Leleu X, Arnulf B, et al. Bortezomib, melphalan, and dexamethasone for light-chain amyloidosis. *J Clin Oncol*. 2020;38:3252-3260.
- Lachmann HJ, Booth DR, Booth SE, et al. Misdiagnosis of hereditary amyloidosis as AL (primary) amyloidosis. *N Engl J Med*. 2002;346:1786-1791.
- Poterucha TJ, Elias P, Ruberg FL, et al. False positive 99mTc-pyrophosphate scanning leading to inappropriate tafamidis prescriptions. *J Am Coll Cardiol Img*. 2021;14:2042-2044.
- Riefolo M, Conti M, Longhi S, et al. Amyloidosis: What does pathology offer? The evolving field of tissue biopsy. *Front Cardiovasc Med*. 2022;9:1081098.
- Picken MM. Diagnosis of amyloid beyond Congo red. *Curr Opin Nephrol Hypertens*. 2021;30:303-309.
- Rauf MU, Hawkins PN, Cappelli F, et al. Tc-99m labelled bone scintigraphy in suspected cardiac amyloidosis. *Eur Heart J*. 2023;44(24):2187-2198. <https://doi.org/10.1093/eurheartj/ehad139>
- Alreshq R, Cozzolino M, Lilleness B, et al. Light chain testing abnormalities among patients with transthyretin amyloid cardiomyopathy referred for technetium-99m pyrophosphate imaging. *Am J Cardiol*. 2022;181:105-112.
- Sidiqi MH, McPhail ED, Theis JD, et al. Two types of amyloidosis presenting in a single patient: a case series. *Blood Cancer J*. 2019;9:30.
- Donnelly JP, Gabrovsek A, Sul L, et al. Evidence of concurrent light chain and transthyretin cardiac amyloidosis in 2 patients. *J Am Coll Cardiol CardioOnc*. 2020;2:127-130.
- Wisniewski B, Wechalekar A. Confirming the diagnosis of amyloidosis. *Acta Haematol*. 2020;143:312-321.
- Markowitz GS. Dysproteinemia and the kidney. *Adv Anat Pathol*. 2004;11:49-63.
- Bennhold H. Specific staining of amyloid by Congo red. *Munch Med Wochenschr*. 1922;69:1537-1538.
- Alexander MP, Dasari S, Vrana JA, et al. Congoophilic fibrillary glomerulonephritis: a case series. *Am J Kidney Dis*. 2018;72:325-336.
- Churukian CJ. Improved Puchtler's Congo red method for demonstrating amyloid. *J Histochemol*. 2000;23:139-141.
- Marcus A, Sadimin E, Richardson M, et al. Fluorescence microscopy is superior to polarized microscopy for detecting amyloid deposits in Congo red-stained trephine bone marrow biopsy specimens. *Am J Clin Pathol*. 2012;138:590-593.
- Leung N, Nasr SH, Sethi S. How I treat amyloidosis: the importance of accurate diagnosis and amyloid typing. *Blood*. 2012;120:3206-3213.
- Larsen B, Mereuta O, Dasari S, et al. Correlation of histomorphological pattern of cardiac amyloid deposition with amyloid type: a histological and proteomic analysis of 108 cases. *Histopathology*. 2016;68:648-656.
- Siegismund CS, Escher F, Lassner D, et al. Intramyocardial inflammation predicts adverse outcome in patients with cardiac AL amyloidosis. *Eur J Heart Fail*. 2017;20:751-757.
- Bergström J, Gustavsson A, ellman U, et al. Amyloid deposits in transthyretin-derived amyloidosis: Cleaved transthyretin is associated with distinct amyloid morphology. *J Pathol*. 2005;206:224-232.
- Schönland SO, Hegenbart U, Bochtler T, et al. Immunohistochemistry in the classification of systemic forms of amyloidosis: a systematic investigation of 117 patients. *Blood*. 2012;119:488-493.
- Vrana JA, Gamez JD, Madden BJ, et al. Classification of amyloidosis by laser microdissection and mass spectrometry-based proteomic analysis in clinical biopsy specimens. *Blood*. 2009;114:4957-4959.
- Picken MM. Amyloidosis-where are we now and where are we heading? *Arch Pathol Lab Med*. 2010;134:545-551.
- Lavatelli F, Brambilla F, Valentini V, et al. A novel approach for the purification and proteomic analysis of pathogenic immunoglobulin free light chains from serum. *Biochim Biophys Acta*. 2011;1814:409-419.
- Satoskar AA, Burdge K, Cowden DJ, et al. Typing of amyloidosis in renal biopsies: diagnostic pitfalls. *Arch Pathol Lab Med*. 2007;131:917-922.
- Stein AP, Matthia EL, Petty SA, et al. Transthyretin cardiac amyloidosis disguised as light chain amyloidosis, or multiple myeloma? *Am J Cardiol*. 2024;210:85-92. <https://doi.org/10.1016/j.amjcard.2023.10.031>
- Linke RP. Routine use of amyloid typing on formalin-fixed paraffin sections from 626 patients by immunohistochemistry. In: Picken MM, Herrera GA, Dogan A, eds. *Amyloid and Related Disorders*. Springer; 2012:219-229.
- Arbustini E, Verga L, Concardi M, et al. Electron and immuno-electron microscopy of abdominal fat identifies and characterizes amyloid fibrils in suspected cardiac amyloidosis. *Amyloid*. 2002;9:108-114.
- Fernández de Larrea C, Verga L, Morbini P, et al. A practical approach to the diagnosis of systemic amyloidoses. *Blood*. 2015;125:2239-2244.
- Quarta CC, Gonzalez-Lopez E, Gilbertson JA, et al. Diagnostic sensitivity of abdominal fat aspiration in cardiac amyloidosis. *Eur Heart J*. 2017;38:1905-1908.
- Rodriguez FJ, Gamez JD, Vrana JA, et al. Immunoglobulin derived depositions in the nervous system: novel mass spectrometry application for protein characterization in formalin-fixed tissues. *Lab Invest*. 2008;88:1024-1037.
- Vrana JA, Theis JD, Dasari S, et al. Clinical diagnosis and typing of systemic amyloidosis in subcutaneous fat aspirates by mass spectrometry-based proteomics. *Haematologica*. 2014;99:1239-1247.

45. Brambilla F, Lavatelli F, Di Silvestre D, et al. Reliable typing of systemic amyloidoses through proteomic analysis of subcutaneous adipose tissue. *Blood*. 2012;119:1844-1847.
46. Alehashemi S, Dasari S, de Jesus AA, et al. Anakinra-associated amyloidosis. *JAMA Dermatol*. 2022;158:1454-1457.
47. Canetti D, Brambilla F, Rendell NB, et al. Clinical amyloid typing by proteomics: performance evaluation and data sharing between two centres. *Molecules*. 2021;26:1913.
48. Theis JD, Dasari S, Vrana JA, et al. Shotgun-proteomics-based clinical testing for diagnosis and classification of amyloidosis. *J Mass Spectrom*. 2013;48:1067-1077.
49. Dasari S, Theis JD, Vrana JA, et al. Clinical proteome informatics workbench detects pathogenic mutations in hereditary amyloidoses. *J Proteome Res*. 2014;13:2352-2358.
50. Mereuta OM, Theis JD, Vrana JA, et al. Leukocyte cell-derived chemotaxin 2 (LECT2)-associated amyloidosis is a frequent cause of hepatic amyloidosis in the United States. *Blood*. 2014;123:1479-1482.
51. Bois MC, Dasari S, Mills JR, et al. Apolipoprotein A-IV-associated cardiac amyloidosis. *J Am Coll Cardiol*. 2017;69:2248-2249.
52. Valleix S, Verona G, Jourde-Chiche N, et al. D25V apolipoprotein C-III variant causes dominant hereditary systemic amyloidosis and confers cardiovascular protective lipoprotein profile. *Nat Commun*. 2016;7:10353.
53. Van Treeck BJ, Dasari S, Kurtin PJ, et al. Somatostatin-derived amyloidosis: a novel type of amyloidosis associated with well-differentiated somatostatin-producing neuroendocrine tumours. *Amyloid*. 2022;29:58-63.

KEY WORDS AL, amyloid, ATTR, cardiac amyloidosis, histology, typing